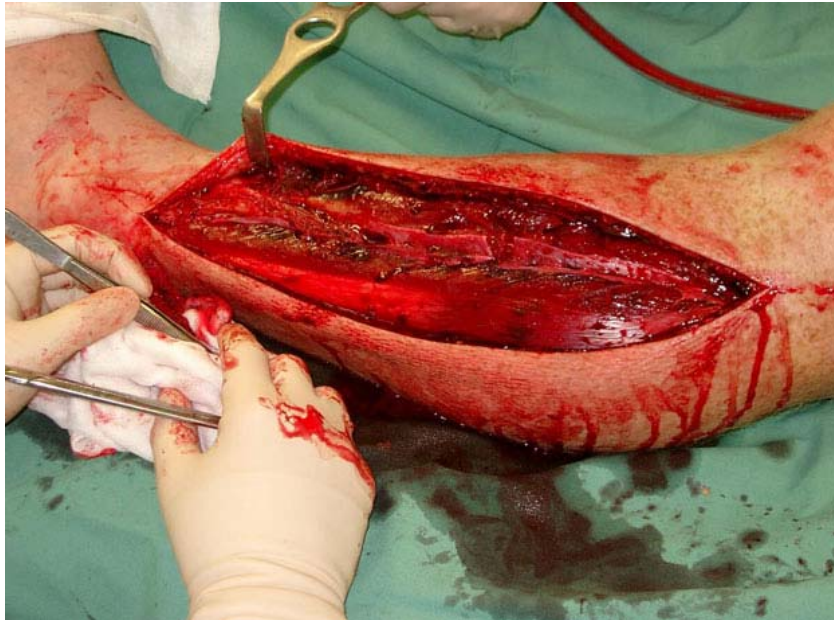

Occasional Papers of the Cape Fear Serpentarium

Is fasciotomy for you?

Bite by *Lachesis* or *Bothrops* –Who’s who? Muscle necrosis – is surgery warranted? Origins of snakebite treatment: therapeutic exorcism?

by Dean Ripa © 2001; 2003



IF THERE IS A MORE INEXACT STUDY than the demographics of snakebite, I can't imagine what it could be. You start out with a panic stricken victim who knows only some folk names for snakes and may not even have seen what creature bit him, and you finish with a doctor whose own set of folk names may not even coincide. If the victim dies, it must have been one of the "deadly" ones; if he lives, it must have been one of the "less dangerous" ones—and to that end the bite shows up in the records. Next you have "official sources" who may not even be in the health care business, lumping the accident in among all the other fatal intoxications in the region, from food poisoning to drug overdose. At last comes the snakebite specialist from overseas who is has in mind to publish a paper—after that, you can *smell* the data cooking! Meanwhile, the snake is still in the woods and has not said a word about it. Of those involved, he is the wiser.

So I feel a little uneasy quoting the latest projections on world snakebite, with their fine details of incidence, morbidity, lethality and mortality, all neatly divided up from the real mishmash. The most venomous species get blamed over and over, while their not-so deadly cousins are repeatedly exonerated. Once in a while a so-called "positive ID" is made, although you never quite understand how the mere addition of a little protein in people's veins can produce so profound an improvement upon their recognition skills. It will take some coaching above the hospital bed to reduce the size of the villain to feasible proportions. While the folk names swing back and forth giddily between surviving family and friends, and the debacle begins as to what laid little Pedro to rest, or sent old Guilherme to the big expensive hospital in the city, two culprits rear their poisonous heads: a snake of unknown kind and size, and a doctor, who may not have had the least idea how to treat the case.

Some doctors, of course, really do save lives, and some victims know exactly which snakes have bitten them. Nevertheless, this percentage is proba-

* **To cite this article:** Ripa, D. 2003. Is fasciotomy for you? in *The Bushmasters* (Genus *Lachesis* Daudin, 1803) Morphology in Evolution and Behavior; 3rd Edition. Electronic book. Cape Fear Serpentarium. Wilmington, NC.

bly not very high in tropical countries. In the Old World with its kraits, mambas and cobras this is a more serious issue than in the Americas, owing to the delayed effect of some envenomings which may resemble harmless snakebites almost till the very end. In these cases, the formula is usually to wait for symptoms. But waiting on symptoms in a krait bite is like waiting for the coroner; by the time the typical breathing difficulties appear, it may be too late to alter the course. Then there is “delayed presentation,” a problem occurring pretty much everywhere there are snakebites. The case may be three days into gangrene before the doctor sees it, putting the initial symptoms so far along that what began as a battle against a deadly venom is now a war against an even deadlier bacteria. Home-remedies ranging from tourniquets to poisonous leaves add to the melee. Assuming none of this happens, that all the right things are in place—smart doctor, early presentation, and good, clearly diagnosable symptoms—then one can start picking out an antivenom. Polyvalent serums can simplify treatment, at least regionally, so in some instances this seems hardly important. However, the bites of certain species require special attention, not only as regards the type of antivenom to use (e.g., “neurotoxic” crotalids in the Americas), but in the whole therapeutic approach. Genus *Lachesis* is one of these, and confusion with the more common and similarly colored *Bothrops* could make a significant difference with the approach to treatment. Fortunately, some variations in early presentations exist. In this section I review bushmaster morbidity, and compare envenomings with its more common congeners, showing ways for distinguishing between the bites when the snake has not been seen or has possibly been misidentified.

Statistically, bushmaster bite shows a low morbidity, but high mortality in all parts of its range (Bolaños, 1982; Gutiérrez et al., 1995; Hardy and Silva, 1998). By contrast, terciopelo (*Bothrops asper*) bite shows a low mortality, but (as with all *Bothrops*) an overwhelmingly greater bite incidence (Gutiérrez et al., 1980). Yet there is a disparity, for as Hardy and Silva (1998) note, “...venom yields and LD₅₀s from the laboratory suggest that the terciopelo is potentially more lethal than the *matabuey* [bushmaster, *L.*

stenophrys] in terms of an individual human envenoming... [The bushmaster has] a proportionally smaller head and venom gland (pers. obs), smaller initial venom yield (233 mg)... [lower] maximum yield of 407 mg (Da Silva et al., 1989) and lower i.v. venom toxicity for laboratory mice (LD₅₀ 5.6 µg/g in mice).”^{*} Contrasting the very high mortality rate of bushmaster bite to the significantly lower mortality rate of the terciopelo, the authors conclude, “The lesson to be learned is that mice are not human beings. The variation in susceptibility to snake venoms makes extrapolation of lethal doses from one species to another an exercise in futility.”

The truth is that if we compared the LD₅₀s of the majority of snakes with the medical data, we would find that bushmasters were not so unusual in this regard. Numerous snake species frequently implicated in fatality would be determined in the laboratory to be unequipped to do so; while some for which fatality records were rare would be deemed gravely venomous (Chapters 24 - 25). But the medical record is distorted by its own artifacts.

Chapter 5 (and Table 8) explores the sizes attained by *Bothrops* species and shows that at least one of them, the terciopelo (*B. asper*) is quite similar to *Lachesis* in length and may even outstrip it in modern Central America. Large female *B. asper* reach 2 m or greater, are not rare snakes, and in any event, much more often encountered than bushmasters by native people. The really big *Bothrops* are soon killed out from agricultural areas, leaving smaller examples to assume their place reproductively. No matter, the dimensions of the venomous apparatus remain nearly the same. The head-size (venom gland and fang size) of an adult female *B. asper*, at 1.7 m length, is not much less than that of a specimen of 2 meters, and capable of expending huge amounts of venom in a bite. The really big terciopelos (> 2 m in length) occur mostly in secondary forest situations (cohabited by occasional bushmasters), around small farms, and not near the modern mass agricultural projects where snakebite is less common. As with bushmasters, these larger adult individuals likely account for the minority of bites. They are more conspicuous, easily avoided, and live in more remote situations

^{*}*L. stenophrys* 5.5 mg/kg i.v. and 6.2 mg/kg intraperitoneally (i.p.) (Bolaños, 1971); 95 µg i.v. (5.6 µg/g) and 110.5 µg i.p. (6.5 µg/g) in 16-18 g mice (Bolaños, 1972) and 112 µg (6.6 µg/g) in 16-18 g mice; and for *L. melanocephala* 8.9 µg/g. For *L. stenophrys* in Colombia 9.8 µg/g (Bolaños et al., 1978), and 6.8 µg/g for *L. stenophrys* from the Pacific Coast of Colombia (Otero et al., 1992). For *L. melanocephala* the LD 50 was 103 µg i.p. (6 µg/g) in 16-18 g mice (Gutiérrez et al., 1987).

This brings us to our first artifact. Statistics attempt to implicate species in snakebite morbidity, but they almost never record the *size* (or at least an accurate size) of the individual specimen involved. While bushmasters and terciopelos are comparably large snakes, the lower mortality for the terciopelo (than bushmaster) may be due in great part to the generally large average size of the bushmasters that usually bite humans, these being almost entirely adult snakes, while the terciopelos involved in snakebite are almost entirely examples of small size, usually juveniles or neonates. But this has nothing to do with the potential of *Bothrops* to reach large size, for these are at least as common, if not more common, than the large *Lachesis*. It has to do with the extraordinary reproductive potential of *Bothrops*, where at any given time babies and juveniles outnumber adults.

Fecundity and snakebite

The average wild-caught bushmaster measures almost exactly 2 meters. Bushmasters are found so exclusively at this size that hunters, collectors, and wildlife dealers consider finding smaller ones a rare event, while the odds of finding a baby bushmaster is probably less than one in twenty adults (Chapter 5). Since finding even an adult bushmaster is a rare thing, this puts babies in an even more remote category. Fittingly, envenomings by baby bushmasters are almost unknown in the literature. Torres et al. (1995) mention a single case of the bite of a “juvenile” snake, but this specimen is of unspecified size and age. Prior to my own bites recorded in Chapter 22, bites by truthfully “baby” bushmasters had never been recorded. Thus the encounter rate reflect almost entirely bites by adult examples, and with almost none at all by the neonate. But we have a disparity, for in *Bothrops* this is quite the reverse. Here neonate and juvenile bites outnumber those of adults by many, many times.

This is easy to prove, both from personal interviews with the bite victims, and from the treatment data itself, where the sizes of the snakes can to some extent be inferred by the anatomical placement of the bites. In Costa Rica (probably the country best documented), about 50 percent of all bites occur on the bare feet, and 32 percent on the upper extremities, mostly the hands (Bolaños, 1982; Gutiérrez et al., 1995). People step on the snakes bare footed, or accidentally put their hands on them. These snakes are undoubtedly small examples whose inconspicuous size has rendered them unseen. The majority of these accidents are believed to involve *Bothrops*, and as these are most populous,

this is reasonable. Without, however, implicating the probable sizes of these *Bothrops* as yet (but see below), let’s compare these with accidents involving bushmasters, whose body length we can almost always assume to be in the 2 m range.

Here the clinical data suggests a different anatomical site than that involving *Bothrops*, primarily involving the lower limb, but not the feet. Bushmasters bite higher up on the body (knees, calves, ankles, etc..) resulting from a long striking range and great body length. It is reasonable that large *Bothrops* would follow this example, and strike high. With only 18 percent of all bites on the legs above the feet, we can conclude that this percentile does not involve neonates and juveniles. Therefore, large adult *Bothrops* bite people not more than about 18 percent of the time. This puts them in the least category of bite incidence, while the greater, 82 percent, involve their smaller conspecifics. Deductively then, we can reason that about 82 percent of all snakebites in Latin America (50 percent foot bites and 32 percent hand bites) are caused by snakes smaller than the average-sized bushmaster (or adult terciopelo) of 2 m length.

How curious that baby bushmasters never bite anybody, but that baby *Bothrops* bite the most people of all! Indeed, it is the baby, not the adult *Bothrops* that are causing the overwhelming majority of snakebites! What makes this so? The answer lies in the remoteness of the habit where baby bushmasters are hatched, and the incredible fecundity of *Bothrops*, which deliver their enormous litters of fifty or more living young near human traffic. During the first months of the birth season, which occurs in September through December (Solórzano and Cerdas, 1989; and pers. obs), a hectare of reclaimed agricultural land could be inherited by literally *hundreds* of neonatal *Bothrops*, with only two or three adult females necessary to produce this number. Most of these babies will not survive to become adults; nevertheless, they will survive long enough to plague snakebite statistics. The records are therefore much biased with the bites of these smaller, inconspicuous, and more numerous babies. Bites by their much less populous parents are logically in the minority, vastly exceeded in number by the younger, smaller snakes.

We can predict less severity in the bites of smaller snakes than large. Bites by baby *Bothrops* should seldom be fatal to adult humans, even without treatment; on the contrary, the bites of large *Bothrops* should often be fatal to adults even with treatment.

So this is a strong artifact affecting our comparison. We can predict that highly fecund species like *Bothrops* will figure more extensively in snakebite statistics than those whose recruitment rate is less prodigious; further, that bites by the less venomous but more numerous juveniles of these species will always be in the great majority. In Africa we should see a similar corollary with *Bitis*, where bites by the very prolific *B. arietans* and *B. gabonica*, for example, will again reflect statistics gathered after the bites of baby or young snakes, most of the time. This accounts for the lower than expected mortality rate from envenomings of these formidably armed species, and others of their ilk.

There are other artifacts. *Bothrops* has a strong sexual size dimorphism, producing a dramatically smaller male with a much smaller head (i.e., less venom and shorter fangs), than the female. Even when the adult male *Bothrops* totals equal length with the female, the male will be less than half her mass. The diminutive male is more commonly encountered than the larger female, by about 2:1 (my collecting data). The degree to which the drastically smaller male (than the female) figures in snakebite incidence is certainly unknown. Yet we can assume that bites by the smaller males occupy the greater portion of the 82 percentile of foot bites and hand bites, their smaller size making them difficult to see and avoid, than females. With their lower encounter rate, the larger females should (or could) be culled primarily from the 18 percent bites to the lower limb above the foot. The bites from larger snakes should then be the most often fatal. This is important, for we begin to see that very grave or rapidly fatal *Bothrops* syndrome (of bleeding to death despite treatment), is a female biased equation. The male, being less than half the mass of the female, and with its dimorphically much smaller head (and venom glands and fangs), will be the less venomous of the sexes.

Bites by large snakes are potentially more severe than bites by smaller snakes of the same species, owing to a larger volume of venom and longer fangs. A subcutaneously administered *Bothrops* toxin is dramatically less potent than an intramuscularly injected one, and if administered by a neonate in proportion to its available venom, perhaps could not even kill an adult human being (Chapters 24 - 25). Death from *Bothrops* bite in adult human beings should, then, always require the necessary fang length to permit intramuscular/intravenous inoculation. Based on venom yield and laboratory toxicity, it seems probable that if bites by 2 m long *Bothrops* predominated (as they do for

Lachesis) the mortality rate would be much higher than now. Extrapolated from tests on rodents (but we cannot vouch for this accuracy in humans), a large terciopelo possesses enough venom to kill 20 or more people if injected by the intramuscular route (up to 1530 mg; Bolaños, 1982). Its fangs are even longer and stouter than the bushmaster's; indeed, *B. asper* has the longest fangs of any snake in the world, exceeding 3 cm in large specimens (usurping *Bitis gabonica* from that honor; see Chapter 11). The chance of these formidable weapons striking an important blood vessel is as great as in the bushmaster, and intramuscular injection is assured. When snake-size is equal, the fatality rate for *Bothrops* bite should as high as *Lachesis* bite.

The higher than expected survival rate for *Bothrops* envenoming is a statistical effect, and not the least bit factual when applied to bites by large females. It is skewed by a preponderance of bites by immature snakes (ca. 50 juveniles to one adult female born each year; thus 50:1), and of the dimorphically smaller males (conceivably > 2:1 females). As such, when we talk of *Bothrops* bites and compare lethality to other species like bushmasters, our terms are not sufficiently descriptive. Factually speaking, we are not talking about a single type of bite at all. So different are the venomous capabilities of juveniles, males and females, it is as though we were not even talking about the same species.

What's in a name?

Names don't mean much in the backwaters of the tropical world. Here the snakes are merely actors in a hereditary drama where the biggest species get first billing and the most credit for killing the patrons. Local monikers like *matabuey*, *cascabel muda*, *surucucu*, *makasneki*, and *verrugosa*, etc., answer for any large-headed, rough-scaled serpent that is not the familiar boa constrictor and has a reputation for mayhem. The woods may be full of terciopelos, but the largest terciopelos are, by some marvelous conversion, *bushmasters*. Size is the native standard by which the names for bushmasters are applied—and misapplied. The scientist not taking this problem into account will make more of local names than is their due, and impose an even greater sense of disorder upon his statistics.

If most terciopelo bites are by baby or young snakes, a bite by a neonate bushmaster cannot be substantiated by a single verifiable case. The literature describes an envenoming by something vaguely called a "juvenile" (in Torres et al., 1995), but this would seem to

cover a broad area of possible dimensions: what is a “baby” and what is a “juvenile” in relation to snake-age and snake-size? Subjectively speaking, a neonate could be anything from 1 day to 6 months old, depending on the reporter’s whim. A juvenile could be all these, more than a year old and a meter long. This size difference would have profound consequences on the recorded severity of the bites. If neonate and subadult (< ca. 100 cm) bushmasters were included in the statistics to the extent of neonate and subadult (< ca. 100 cm) terciopelos, what would be the result? Certainly we would see fewer bites involving the lower limbs (which comprise most non-interactive bushmaster bites to date) and more bites involving the feet and hands. In all likelihood, however, misidentification would prevent these examples being called “bushmasters” to begin with. The local vernacular would connect them with several typically smaller, more familiar species, and not with *Lachesis*.

Bushmasters are nowhere plentiful, but none less than the almost supernaturally rare babies. Offering a bounty in Costa Rica, Panamá, Suriname, Ecuador, and Brazil, I observed this mystery first hand. Once in a while the native catchers would bring in a fairly young example (< 40 cm), but in no case a newborn bushmaster prior to its first skin shed; nor all my years tramping through bushmaster habitat was I ever blessed by an encounter with a baby bushmaster myself. Such young specimens (> ca. 6 months) as were brought in were remarkably few, always outnumbered by the perennial 2 meter adults. Nearly all specimens were found in forest that was being slashed for agriculture. By contrast, approximately 20 baby/juvenile (< ca. 100 cm) *B. asper* were taken, to every one large (> 1.6 meter) adult of that species, these numbers snowballing in the birth season. As in collecting, where it is the large, 2-meter-long adult bushmaster that is most often encountered, it is the adult bushmaster bite that has most often found its way into snakebite statistics, to the extent that it dominates all others. Even if newborn or small bushmasters did often bite people, and were abundant in agricultural areas and near human dwellings like terciopelos, the chances of them being described statistically, is small. The tendency would be to absorb these bites into the greater morbidity of *Bothrops* and related genera. For example, the little tamaga (*Porthidium nasutum*) makes such a convincing “baby bushmaster” that most of my collectors could not tell the difference even after I had provided them with photographs. This proved true in all regions where *Lachesis* overlapped with *Atropoides nummifer*, as well; and even in regions where they did not overlap, owing to the transient human populations who had experience

with them. Jumping vipers became bushmasters when bushmasters were more than about 1 meter’s length.

Rural doctors are not well educated to tell the difference either, confusing *Bothrops* (*asper*, *atrox*, etc.) with other venomous ground vipers as a matter of course. Whether the bite is by one of the *Porthidium* species, or any other potentially less venomous kind, the easy path is to blame it on the better known terciopelo (or other *Bothrops* taxa). As with the bushmaster, few rural Costa Ricans bother to distinguish between the much less venomous tamaga (*P. nasutum*) and the terciopelo. One is simply the “baby” of the other. Hence an enormous number of bites attributed to the terciopelo may in fact involve the little tamaga.

There are other confusions of size. For example, when a terciopelo reaches about 2 meters in length it automatically becomes a matabuey in the popular mind. It can do what its name implies—*kill an ox*—so why not? *Matabuey* (ox killer) and *cascabel muda* (silent rattler), although names intended for bushmasters, means a viper of large proportions, little more. For example, when I put out a bounty for live matabuey in rural areas near primary forest, I was disappointed to receive almost all large terciopelos (>1.5 m) until my catchers (and in turn their catchers, for they were quick to make a business of it) learned to tell the difference. Hence, to be bitten by a large terciopelo was to be bitten by a matabuey, as far as the local people were concerned. With inverse logic, bites by baby bushmasters would probably have been blamed on terciopelos (or else on tamagas, which is what the few baby bushmasters brought to me by native collectors were typically called), had any occurred. In effect, to many residents there were no small bushmasters, only terciopelos, just as there were no large terciopelos, only matabuey. I have encountered similar phenomena in all parts of the bushmaster’s range. Even in mainland South America local collectors confused the smaller *Bothrops atrox* with bushmasters, once the *Bothrops* exceeded a certain size.

Identification through symptoms

All this reflects statistically when doctors start asking their patients what bit them. They may be left with only the symptoms to identify the culprit, and yet building a picture of snakebite according to this sort of diagnosis is a haphazard affair, for the treatment protocols for bushmaster are very different. In the next

pages I devise a workable diagnostics based on visible alterations easily seen on presentation, and that will hopefully make treatment simpler and more successful.

In cases of severe envenoming, differential diagnosis of *Lachesis* with *Bothrops* can be summed up by two words: *shock* and *hemorrhage*. If the victim presents skin blistering or blackening of local tissue, or any systemic hemorrhagic sequelae within a short time frame (ca. 5 hours) after the bite, the culprit is *Bothrops* and not bushmaster. Reports in literature, TV nature programming, etc., of bushmaster bites causing “bleeding from eyes, nose and mouth” are undoubtedly based on misidentification by resident persons. However, systemic alterations such as early shock (i.e., hypovolemia) are definite signs of bushmaster envenoming. Although there is no doubt that the bite of a large terciopelo could produce shock effects analogous and as severe, these would likely be delayed and already accompanied by some visible blood incoagulability and/or early skin necrosis. Indeed, posing so severe an envenoming from *Bothrops* that it would produce the rapid systemic alterations of bushmaster bite is to pose concomitant hemorrhage, with extravasation, thrombocytopenia, multiple local hematomas, and systemic hemostatic disorders including mucosal bleeding (e.g., epistaxis), hemathidrosis, occult bleeding in the GI and GU tracts (presenting as hematemesis, hematochezia, urticaria, &c.), and in severe cases, deep visceral hemarthrosis. Renal and hepatic bleeding and even cerebral hemorrhage are an expected prognosis. In bushmaster bite, the patient would already have died from shock before these delayed effects could take place. If he were not experiencing severe shock to go with his free-bleeding, then it would not be a bushmaster that had bitten him (see descriptions of bushmaster bite shock, i.e., *Lachesis*-syndrome in Chapter 22).

The effects of bleeding to death can be seen on the small scale in the edematous area surrounding the puncture wounds in *Bothrops*. The latter will turn quickly black, making a blood-blister. Blood and

serum filled bullae will appear on the bitten extremity within as little as 2 to 4 hours and usually before 12 hours (Fan and Cardoso, 1995; and pers. obs). This blistering may advance over the course of days, reaching large size. But there is little or no blistering in bushmaster bite. In the *Bothrops* bite the patient may feel the skin “stinging with fire” throughout the extremity, and be unable to distinguish this feeling from that of an actual fire burn; however, in bushmaster bite, while there is a feeling of a germinating fire (initially), the oncoming sensations of “having one’s limb plunged into boiling oil” may be absent. Bushmaster bite pain is primarily like that of blunt trauma; a concentrated, heavy, pounding ache, emanating from within the muscle and tendons, rather as though one had shut ones hand in a car door and were repeating this operation till a sense of near numbness supervened in tissue no longer equipped to feel anything. Or, if into deep muscle, the pain may take the feeling of impalement, as of a sharp dagger plunged through the limb and being twisted back and forth. The pain is mindboggling, and may be so severe that the victim’s teeth chatter and his whole body jumps convulsively. For all that, the feeling of fire-burn is mostly absent, probably from the venom being less hemorrhagic. The pain dulls down after some days to a crashing repetitive throb, and you can tolerate it. In *Bothrops*, however, the fiery pain is continuous, and feeling of “flames” dancing transiently about the limb in areas remote from the inoculation site, may persist for more than 6 weeks. In *Bothrops* bite, the fang punctures will always turn black, and if presenting as dark blue or purple will soon turn black, while the bite wounds and/or surrounding areas will blister. In bushmaster bite the wounds may appear darkly bruised, but they are basically clear and will not necrotize (but if any necrosis occurs at all, it will likely be here). Exorbitant edema may give the skin an appearance of near bursting.* If blood escapes beneath the skin surface (extravasation), it will be due mostly to the pressure of the swelling rather than from the degradation of the blood vessels by the venom. If sufficient antivenom is given soon enough there should develop little or no skin discoloration other than bruise-

* Bushmaster envenoming produces some of the most extreme edema of any snake species. I have endured swelling so tense that even to twitch the fingers or elbow was to cause the skin to split open. Nevertheless, I believe fasciotomy to relieve compartmental pressure is never indicated in these or any other species. It causes permanent scarring, increases likelihood of infection and advances necrosis. Moreover, it prolongs and exacerbates deadly shock. The dangers of compartment syndrome are wildly exaggerated. Watt (1989) notes, “Tense edema in the bitten limb rarely leads to vascular compromise.”

ing. Not so with a *Bothrops* bite, where the blood from ruptured blood vessels always turns black, having hemorrhagic or necrotic contents. The fang wounds in the bushmaster bite may cease bleeding within a few minutes of the inoculation, the pressure of the swelling literally closing the wounds shut, although there may occur a clear serous discharge. With prompt and sufficient antivenom the fang wounds will rarely abscess, except from secondary contamination. In the *Bothrops* bite, the fang wounds will turn black regardless of antivenom treatment and will almost always abscess with bloody pockets of hemorrhagic cellular debris regardless of infection. Note that a “venom abscess” reflects the hemorrhagic properties of the venom and is distinct from a bacterial abscess, but both may occur in concord. A scorched-looking, blackened limb covered with bullae and growing hard with necrosis is not from the bite of the bushmaster. It is the signature of the *Bothrops*.

Silva (1980/81) made the first attempts to differentiate these symptoms diagnostically. His conclusions reflect bites by *Lachesis muta muta* so they may differ somewhat from my first hand reports of bites by the Central American species, with respect to skin necrosis (perhaps greater in *L. muta muta* although still milder than in *Bothrops*); however, the systemic effect remains remarkably similar. Cardiovascular changes occur within 15 minutes of the accident, with severe hypotension, bradycardia, blurred vision, intense abdominal pain, colic, diarrhea, and vomiting before 1 hour. In *Bothrops*, he concludes, the hypotension occurs much later, 10 hours or more after the accident. And as I have reported in the previous chapter, hemorrhagic effects are much more intense in *Bothrops* and may be altogether lacking in *Lachesis*.

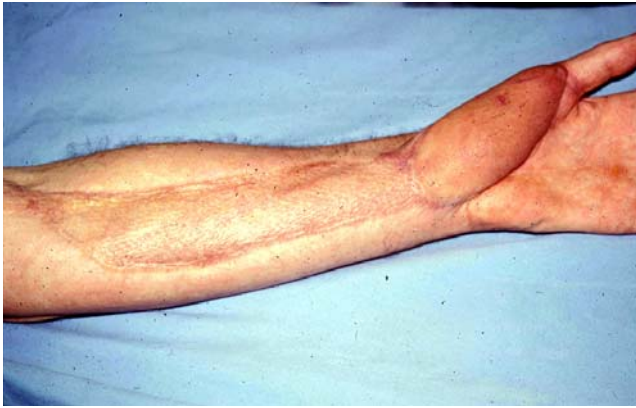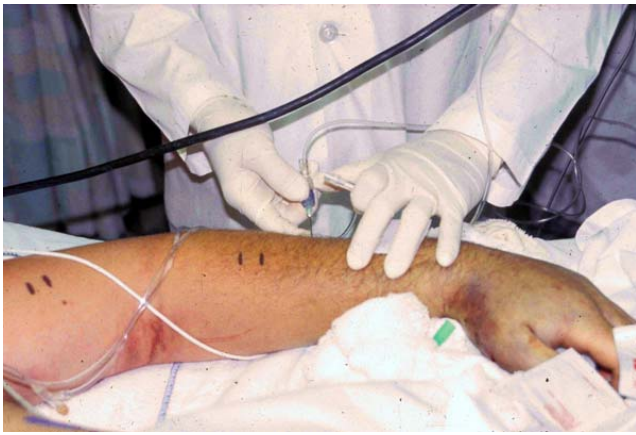As noted from my own bite experiences, a distinction should be made about the “abdominal pain” syndrome associated with bushmaster bite. This has been attributed, wrongly, I believe, to colic and diarrhea. Although the latter occurs in consort, the stabbing pains are not gastric in origin. If they are not actually nerve-related (e.g., from vagal stimulation), they are more nearly distributive, related to hypovolemia. This thronging, convulsive, and altogether unique agony is peculiar to what I have dubbed the “*Lachesis*-syndrome.” Chapters 25 - 26 explore new data and pursues this theme further.

Muscle necrosis—is surgery warranted?

Muscle necrosis has been reported in bushmaster bite, historically in a review of four cases of *L. stenophrys* bite in Costa Rica (Bolaños, 1982); in a case of *L. muta muta* bite in Colombia (Hardy and Silva, 1997); and more recently in an interactive bite involving a professional snake-catcher, also in Costa Rica. In all cases the muscle necrosis was encountered during fasciotomy-incision, relatively soon after the bite (within four days). In all cases the muscle necrosis was described as “extensive.” All patients received varying amounts of antivenom therapy, however, in the Colombian case antivenom was given sparingly, and long after the bite occurred. In this section I review these cases, and compare them to my own bites and some others. I review the effects of surgery in bushmaster envenomations, and conclude overwhelmingly that it causes serious deficit and leads to death in early treated cases.

Gutiérrez et al. (1990) notes in laboratory tests on mice “abundant erythrocytes and mild myonecrosis in muscle injected with venoms of adult, two-year old and one-year old specimens of *L. stenophrys*.” In these cases, there were abundant erythrocytes in the interstitial space and a relatively small amount of necrotic muscle cells.” In other words, the necrosis, however mild, was always located in areas of abundant hemorrhage. Granting that venom susceptibility in human beings may be different than in mice, the resemblance between hemorrhagic cellular debris to necrosis is certainly striking. Both appear black (or very dark) in color, indurate, and certainly constitute an accumulation of “dead” material. This could provide a convincing mimic of necrosis to physicians unaccustomed to seeing it, and in the resulting anoxia caused by surgery, catch more than a little blame for what it is due. In extremely edematous tissue such a mock necrosis could appear extensive, especially where hemorrhage has been increased by surgery. Significantly, in the five envenomings described in Chapter 22, neither muscle nor skin necrosis occurred. In ten envenomings in Souza and Buhnrheim (1995), necrosis was not a problem. Given these disparities, we can at least concede that a large window of uncertainty exists for an accurate diagnosis of muscle necrosis in bushmaster bite cases.

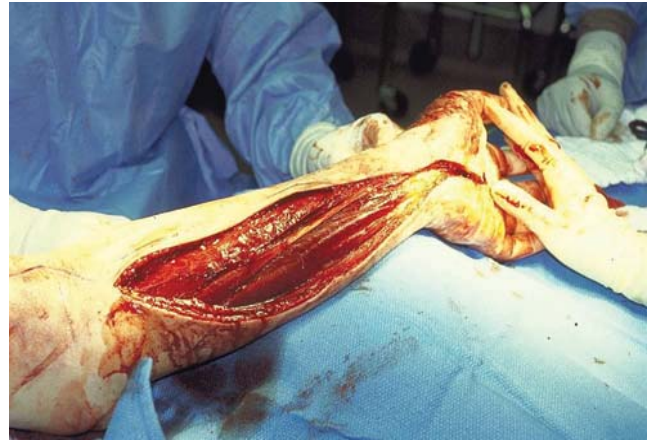
As such, myonecrosis in promptly treated bushmaster bite might be either: (1) confusion with *Bothrops* bite, where the long fangs of the *Bothrops* have delivered the potent myotoxin deep into muscle; (2)



misdiagnosis based on confusion with erythrocytic debris in the muscle cell interstices (sensu Gutiérrez et al., [1990]); (3) tissue anoxia from hemorrhage started by the surgical procedure; or (4) actual myonecrosis.

I strongly suspect that the majority of all early treated bushmaster bites, where sufficient antivenom is given and severe skin and muscle necrosis is reported, are either cases of misidentification of the snake (e.g., it was really a *Bothrops* species), examples of tissue anoxia resulting from secondary infection and/or increased hemorrhage enhanced by surgery (fasciotomy, excision, &c.,) and/or confusion with existing erythrocytic debris also enhanced by surgery. Any of these local alterations could convincingly impersonate muscle necrosis to physicians inexperienced with the effects of snakebite (as most are); especially those physicians persuaded by medical literature to expect myonecrosis in envenomings by all large vipers.

Perhaps medical literature has used the term “myonecrosis” too liberally, not only in regard to bushmaster bite, but in many other snakebites, as well. Russell (1983) remarks on the rare occurrence of necrosis in the North American crotalid envenomings



Fasciotomy after bite from a captive *Crotalus oreganus helleri*. **Figure 2.** Intracompartmental pressure is measured in the arm. **Figure 3.** Intraoperative view of fasciotomy. **Figure 4.** Three years post-bite after skin grafts and muscle transfer. Photos Robert Norris.

he has treated; and I would suppose all of these to possess more strongly necrotizing venoms than *Lachesis*. Fan and Cardoso (1995) note the occurrence of necrosis in less than 10 percent of *Bothrops* envenomings; and in laboratory tests on mice, the venom of *Bothrops* has been shown to have a more necrotic action than that of *Lachesis* (Gutiérrez et al., [1990, 1980], Rucavado et al., 1999). Yet some recent literature on bushmaster bite would have us believe that muscle necrosis occurs in a majority of cases.

Consider the ethical justifications in a medical profession already determined to use surgery for other reasons (e.g., to prevent or relieve a suspected “compartment syndrome; but see below). An averred “muscle necrosis” expiates the damage caused by surgery, and supports the importance of surgery as a valid means of resolving an always uncertain condition. A diagnosed “muscle necrosis” can always be dragged out after the fact even though the surgery itself may have encouraged its development. It is not unexpected that inaccurate or misleading medical reports should find their way into the medical statistics, giving the impression that myonecrosis is rather more common in snakebite than it actually is. Sadly, this may have resulted in many unnecessary surgeries, keeping this expensive and damaging procedure in use as a standard practice. Ultimately, however, the debate over muscle necrosis is less important than the radical methods chosen to deal with it, and vitally, the time-period during when these selected methods

are applied. It is this critical time-period that will have most to do with whether the patient survives or not to pay the medical bill.

Bear in mind that surgery is not usually elected to correct some unseen necrosis whose existence the physician might suspect, but cannot really determine, before opening the bitten extremity. The initial surgery is usually performed to relieve edema. This technique, called fasciotomy, attempts to sever the constricting band of the fascia which, with gross swelling, might cut off the blood supply to the extremity (or is so feared). The fascia, unable to expand with the swelling, becomes a sort of inner tourniquet. Fasciotomy provides an opportunity for other sympathetic invasions afterwards, such as surgical debridement and excision. It gives the physician a chance to see what horrors may be stewing beneath the skin surface. A case of, “well, we were there anyway so we cut out some nasty stuff.” It is difficult to imagine a surgeon zealously exploring for an unknown necrosis in a recently, near fatal snakebite, with all the added systemic trauma this entails, without even the justification of fasciotomy, but we must conclude that this is often the case. Contradicting Watt (1989) who reports “severe local necrosis” in bushmaster bite (probably summarizing Rosenfeld, 1971), I believe that surgical debridement is never indicated under any circumstances, if that surgery is intended to relieve a supposed “venom necrosis.” Even in *Bothrops* envenoming, surgery is probably useful only in managing infection and gangrene (never to be confused with venom necrosis) which usually requires days to manifest, and almost always results from too little antivenom given at the start, and/or previously mismanaged first aid. As Reid (1976) notes (in Russell, 1993): “By using surgery in all cases . . . some necrosis develops in all . . . victims.” In other words, from the moment the first incision is made the patient is already worse off than when he presented.

Watt’s (1989) remark, “Careful, prompt surgical management is the key to minimizing damage in cases complicated by necrosis” is grossly underdefined—just the sort of statement that sends doctors reaching immediately for the scalpel. The medical practitioner inexperienced with snakebite, confronted with the rare case of venom necrosis, believes he is acting for the patient’s benefit, and reducing the overall damage that would occur. Quite the contrary, excepting those very rare instances where surgery has application (e.g., gangrene), surgery should never be attempted “promptly” but only after swelling and inflammation have re-

ceded. This is a period requiring weeks, not hours or days, hence surgery at this time cannot be considered “prompt” by any means. In the first days post-envenoming, with edema, inflammation and hemorrhage at its peak, surgical exploration is diagnostically fruitless: there will be more damage to come. Presented with an oozing extremity distorted by swelling, inflammation and incoagulable blood, all of which will have been aggravated by the surgical incision itself, few if any physicians will be able to distinguish between necrotic tissue and erythrocytic debris in still vascular, living tissue. Yet damage will be increasing day by day. Only after the swelling has receded, and the destructive agents become static, can the true extent of the damage be ascertained. Since local damage evolves slowly even if the spread of venom does not, it is of little worth to “check the cake before it is done.” Because necrosis seems never to start without hemorrhage, it follows that the best way to increase necrosis is to increase hemorrhage; that is, use surgery. And because surgery amplifies the probability of infection, and contributes to the shock state by reducing the blood pressure, it may even kill the patient (see cases below).

Debriding, excising, opening to drain or clean, or in any way breaking the skin surface at the bite site and surrounding areas increases necrosis and results in further degradation of the bitten extremity. Note the bite on Judge Carr, in Mole (1924), where the fang wounds were lanced and his thumb withered to three-quarters normal size; compare to Bites 1-5 (Chapter 22), where the fang wounds were not tampered with and no such damage occurred. There would seem to be no good excuse for using surgery in any bushmaster bite, excepting those cases complicated by poor treatment methods where infection had become a greater issue than the envenoming. In *Bothrops* bite, the black, blistered skin at the fang punctures and surrounding areas should be left undisturbed. This veil of hematose tissue, no matter how gruesome looking, will desiccate and mummify as the weeks progress. Dry and hard and continuous with the still venous skin, it will protect better than any bandage the compromised underlying tissue. Hemorrhagic venom necrosis (as opposed to bacterial necrosis and other variants) is basically a kind of scab, being composed of dead extravasated skin and dried hemolytic debris. Cut or tear off this covering prematurely and the new tissue beneath it will itself hemorrhage, necrotize and/or suppurate, resulting in the formation of yet another such “veil” of dead tissue.

Leave the hemorrhagic-necrotic formation alone, however, and the dead material, given time, will slough off on its own and newly restored skin appear. Since sloughing will not occur until well after the swelling has receded, and the tissue regenerated (ca. 45 - 90 days), attempts to rush healing with surgery are not only pointless but counterproductive. One must not yield to the impatience of expecting an immediate cure to a condition that is irresolvably chronic and somewhat transient, and that requires a long healing time before any improvement can be seen; nor should one yield to the persuasion of physicians anxious to “do something” when doing nothing is the better course (bearing in mind that physicians often take action simply to satisfy the expectations of the patient). Viper bite is not an injury or trauma, it is a disease, a teleomatic program evolving, enlarging, changing, pursuing a course mosaic, never unidirectional. The patient should be informed that he will be participating in this “process” which is first not of healing but of degeneration. Even with prompt treatment, local damage in viper bite will generally worsen throughout the first week, and if serious, continue advancing for more than 20 days. This “program” cannot be arrested with a quick-fix like surgery, and cutting out the damaged area in an effort to “keep ahead” of the venom will only make things a whole lot worse. One must begin by protecting the fang punctures and the eruptions surrounding them. Every effort must be made to keep the tissue from breaking so as to minimize hemorrhage and exposure to air and bacteria. It is precisely where the skin breaks open that necrosis and anoxia forms—hence necrosis first appears within the fang wounds, bleb formations, venepunctures, and other compromised tissue. To preserve the original integrity of the bitten extremity should be the foremost goal, and frankly, cutting it open is not much more sensible than backing your car over it. I suspect the results would be much the same in any event.

The poor overall performance record of surgery in snakebite speaks for itself. Russell (1983) remarks the general worthlessness of surgery in bites by North American crotalids, and Hardy (1992) among others have questioned the use of bite excision. A comparative study of Surgery *vis-à-vis* No Surgery in all snakebite would likely prove my case. Let’s take a look at some bushmaster bites in this regard. Here the track record of surgery cannot be any worse—and can even be linked to the deaths of the patients.

Hardy and Silva (1998) provide 12 “reliably authenticated” envenomings by bushmasters with treat-

ment details. Add to these the 5 interactive bites I described in Chapter 22, and we have a total of 17 bites where management details known. (I have omitted cases of rapid death, and all cases where treatment details are not recorded; I have also included the case in Mole [1924], where the fang wounds were incised.) Here is the score:

Mortalities with surgery	4
Recovery with surgery with lasting physical disability	4
Recovery with surgery without lasting physical disability	0
Recovery without surgery and without disability	9

Even if we acknowledge that the more serious bites that resulted in death and/or caused disability required surgery to correct the problem, we must admit the overwhelming failure of surgery to achieve its goals: *All deaths involved surgery, and all cases involving surgery resulted in serious physical disability.* Without surgery, recovery was 100 percent. There is another common denominator: in all cases ending in death and serious physical disability, all involved surgery prior to 4 days post-envenoming: the surgery was “prompt.”

Bolaños (1982) reports three fatal cases of bushmaster envenoming with surgery, and one case of survival with surgery that resulted in physical disability. “Extensive myonecrosis” was described in all four cases. Note, however, that myonecrosis prior to surgery could not have been known; it was not a preexisting complaint of the patients. Indeed, prior to four days (and surgery) there was no clue to its existence, since a phenomenal lack of skin necrosis was mentioned in all cases (although in one case some minor necrosis was noted in a small area around the fang punctures). In effect, the “myonecrosis” was discovered inadvertently during surgery. Whether this diagnosis was based on confusion with hemorrhagic cellular debris in the muscle interstices (as in the envenomed mice in Gutiérrez et al., 1990), or whether it was actual myonecrosis as specified, is less important than the lamentable outcome of the cases: *three of the four patients died.* They did not die of venom necrosis (a condition so rare as to be unknown), or from the typical hemostatic interruptions of viperine venom. They died from secondary causes, and on

the third and fifth day after the bite. As summarized by Campbell and Lamar (1989), death resulted from “shock secondary to massive swelling, suppuration of tissue, and overwhelming infection.

Readers familiar with the snakebite literature cannot fail to note that these are very strange mortalities. They are even stranger considering the early antivenom treatment. “Shock, tissue suppuration, and overwhelming infection” sound more like the effects of septicemia than venom. While too little antivenom probably laid the groundwork for these deaths (the three patients who died received only 10 vials each; a fourth patient, who received 20 vials, survived) no doubt the surgery didn’t do them any good either. Hardy and Silva (1998), noting from the literature, report that the three patients “appeared to improve during the initial 36 h, but then went downhill despite continued therapy; the fourth patient rallied initially and continued to improve.”

What did this “continued therapy” consist of? Obviously surgery (fasciotomy), during which the “extensive myonecrosis” was encountered and excised. Since surgery (which requires its own supportive therapy in addition to that of the snakebite) would more likely be conducted on an improving patient than one in the death throes (but this only *our* logic, one that surgeons don’t seem to have), we may conclude that it occurred before the 36th hour, that is, before the “improving” patients began to go downhill. Logically, it is likely their conditions worsened *because* of their “continued therapy” (surgery) rather than “in spite” of it. The surgery, occurring prior to 36 h, encouraged the “shock, tissue suppuration and overwhelming infection” that later killed them. Recall that all three patients reached medical help early (before 4 h). All received antivenom and were described as “improving” during the first 35 hours. Yet something suddenly caused them to go “downhill.” Was it surgery?

There is a fourth bushmaster bite fatality that involved surgery: a case of *L. muta muta* bite in Leticia, Colombia. The snake was reported to be over 2.5 meters long (a very large snake). Hardy and Silva (1998) report the victim received a total of six ampoules of antivenom—two within the first 15 h, and four thereafter. Since two ampoules within 15 h of a bushmaster bite is little of nothing (my own severe bite from a much smaller snake required 14 vials, and was administered within 1 h), antivenom treatment cannot be said to have been “prompt”. The 4 ampoules subsequently administered (totaling 6)

seems even more inadequate when we consider the snake’s great size and capacity for injecting multiple lethal doses of venom (Chapters 24 - 25 explores this capacity).

Three days post-envenoming there was evidence of significant infection with ecchymosis. Coagulation tests were “unremarkable,” which suggests that the ecchymosis (in the absence of hemorrhagic bullae) with its long delay, might be due to the intense swelling and infection rather than a hemorrhagic effect of the venom. On the third or fourth day post-bite, the extremity was subjected to “extensive surgical debridement through an anteromedial incision of the lower leg, and extensive hemorrhagic necrosis of the muscle was encountered.” The patient died within 24 hours of the surgery, from “irreversible hypotension.”

Perhaps we have stumbled upon a formula for insuring that bushmaster bite lives up to its reputation and kills the patient regardless of our efforts to save him. This formula consists of two simple ingredients: too little antivenom and a lot of surgery—surgery to remove a muscle necrosis that the surgeon cannot be sure is there until he has operated (during fasciotomy), and perhaps cannot even properly identify once he has; but that is, at any rate, much less dangerous to the patient’s life than the surgery that proposes to correct it. Within the melange of inflamed and nearly unrecognizable tissue encountered once breaking the edematous surface of the skin, the view obstructed by hemorrhagic debris, probably only subsequent putrefaction could make “necrosis” apparent to the surgeon. And such “necrosis” would as likely result from the additional damage of the surgery (from anoxia) as from any verifiable effect of the venom. No matter, even here surgery should fail its task, since in these early days the advancing *process* of the envenoming (for snakebite, as I say, is not an injury, but many, many cumulative injuries evolving along a chemical time-chain) should continue long past the initial incision.

In the four cases in Bolaños (1982), extensive myonecrosis with no skin necrosis is a strange thing. Skin necrosis was seen in only one patient, confined to a small area around the fang punctures. The long fangs had evidently injected the venom so deeply into the muscle as to have bypassed the skin. Since bushmaster fangs may reach 3 cm (and penetrate to a depth of 4 - 5 cm with the compression of the bite) this is not impossible. Yet in my four bushmaster envenomings, and in the bite on the herpetoculturist in

New York State, there was no necrosis of any kind, not even at the fang wounds. With the shock effects that surgical intervention may only extend or complicate, we can see that necrosis is the least of the patient's worries. Even if muscle necrosis were a reliable (and not misidentified) occurrence, surgery to correct it is at best inappropriate during the early days post-venom, and should not be performed until the patient has made a full general recovery. Venom necrosis is not life-threatening—surgery is! Venom necrosis is not bacterial necrosis, which is of a distinct character. The lethal action of bushmaster venom is primarily an effect on blood distribution, and any restorative effort should first concentrate on managing these much more dangerous shock effects, even to ignoring local damage, no matter how dramatic or apparently severe. At no time should surgery be performed on the extremity until the patient is well past the danger zone—when, in other words, systemic alterations have entirely abated.

Surgery advances the hypotensive state and thus precipitates total cardiovascular failure. The physician should be persuaded to note that only after the edema and inflammation has receded (requiring sometimes 6 weeks or even more) can a final appraisal of the local damage be made, and that surgery prior to this time is not only premature, it will aggravate the problem.

To date I have sustained 11 viperid bites. These include: *Atractaspis* (with necrosis), *Causus*, *Porthidium*, *Bothrops asper* (with necrosis), *B. leucurus*, *Bothriechis schlegelii*, an immense *Agkistrodon piscivorus* (when I was a 90 lb, 13-year-old boy; this required 14 days in ICU and a year's ther-

apy to regain use of my right hand). I have had four bites by *Lachesis* species, two in the severe category [Ed. note: Ripa's fifth, sixth, and seventh bushmaster bite predates this text]. All these involved intense pain, inflammation, pronounced and in some cases massive swelling, various degrees of tissue destruction and deficits of mobility resolved only after a very long recovery time. All the bites occurred on my hands or digits. The reader will be heartened to learn, however, that I am typing this manuscript with all ten fingers! Had "prompt surgical management" been performed in each of my cases, I wonder how many fingers I would have left? Indeed, I should by now resemble a

maimed circus freak with flapping noodles for arms and living off disability. And yet I have no discernible scars, save one resulting from the clinical lancing of the fang punctures (in the *Agkistrodon* bite), a relic of the old days when "cut and suck" was still practiced even in hospitals. The other ten bites, despite necrosis

in some of them, healed without scarring. Thus, the only scar I have sustained out of 11 viper bites involved the scalpel!

The literature is a reservoir of vague, unfounded, and misleading diagnoses for under-defined symptoms, crudely drawn against a background of often arbitrarily proposed terminologies. Necrosis, that all-purpose term for any condition where tissue is irrevocably damaged has been blamed more on venom when it should have been blamed more often on bacteria, iatrogenia, and anoxia from surgery. In Figures 17 - 20, I reclassify necrosis according to its causes and symptoms, and suggest that different types of necrosis require different kinds of management.

Another factor commonly misevaluated is the permanency of symptoms. Dart et al. (1992) arbitrarily defines as "permanent" any alterations persisting for

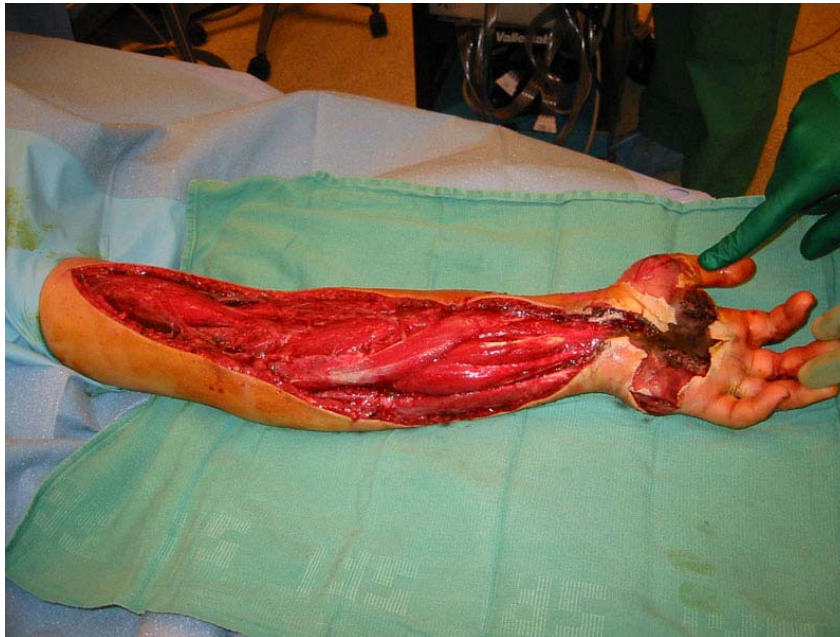


Figure 5 (above). Insane futile fueled by the medical wive's tale of "compartment syndrome." Rattlesnake bite on 13-year-old male treated with fasciotomy.

more than one month. Would that venom finished up with us so quickly! At one month the limb may still be “in the cooker,” as it were, with symptoms still escalating, while in other envenomings the damage will only be starting to recede. Snakebite is not an injury, it is a disease. It is a *process* resulting from an introduced chemistry that, like the cancer whose molecular structure venom more than discretely resembles, advances through stages. *These stages cannot be interrupted by surgery! Only living tissue transmits venom to other tissue!* As in cancer, envenomation is a program in which the victim’s cellular structure and mode of chemical exchange participate in the cell’s own breakdown. Indeed, there are forms of necrosis where the cells so react to the actions of the venom as to mimic it, auto-destroying the tissue and even killing the patient! And this even though the actual venom has been neutralized! This Delayed Hypersensitivity Necrosis (DHN; Figure 17-20) is inspired by anoxia from surgery and is the only kind of venom-induced (non-bacterial) necrosis that can be described as systemic and fatal.

We must be very careful when we speak of permanency in snakebite. Granted this terminology may be only a methodological convenience for classifying some symptoms in a text (e.g., as in Dart et al., *ibid.*), it can only create confusion on the battlefield where use of invasive means hinges on the diagnostic talents of the physician who may thus construe damage lasting longer than one month to be literally permanent and so advise surgery accordingly. In fact, one can expect local alterations in any serious viper envenoming to last for upwards of one to three months as a matter of course. Some deficits may last greater than a year in many cases. Hence, after six weeks when the limb is still livid and swollen and hemorrhagic necrosis has not yet spontaneously resolved (but might if given more time), some physicians might advise invasive means to correct this seemingly “permanent” problem. This can only result negatively for the patient, who should be *patient* a little longer, please—lest he wish his condition to be made to fit the Dart et al. (1992) definition forever. Contracture, joint stiffness, hyperplasia, loss of sensitivity, &c., can be expected to last many months, but these conditions stand a better chance of resolving on their own than with surgery.

Perhaps the danger with the advice given in Watt (1989) and others lies in the vaguely defined terms. “Prompt surgical management” and “complicated by necrosis” are just malleable enough statements as to

be without practical meaning. What exactly are the complications of necrosis and doesn’t surgery itself promote many of them? Doctors naively following Watt’s (1989) advice will have no idea what “prompt” means in regard to necrosis and begin debriding tissue as soon as it appears. By this process well-intended surgeons, through a hideous progression of operations resembling whittling, convert healthy arms and legs into crippled, useless nubs—what I call the “death by a thousand cuts” method. Each week a smiling executioner shows up at your beside and carves off a little more of you—renewing your necrosis into the bargain, at no extra charge! The photography in this chapter discloses some pretty graphic examples.

Hemorrhagic necrosis does not harbor or retain venom—and being dead and non-vascular it cannot further transmit venom to the underlying tissue. It is not literally “rotting flesh” and does not of itself constitute a source of bacterial infection. To remove this hard, desiccated veil of protective tissue is to invite infection into the wound, increasing tissue anoxia and perhaps even enkindling the dreaded catastrophic necrosis (DHN), by which model we observe certain spider venoms (e.g., *Loxosceles* sp) can devour (deflesh) an entire human body over a period of days. And yet here it is not the venom but the body that is eating itself! The venom is only a trigger-mechanism. At least some forms of necrosis are imitative, born of disturbed cellular program-sharing. The cells replace themselves with unfit counterfeits engineered for an early death. Here, the similarity of venom to cancer becomes obvious. Venom is deadly but it is also information. It takes “two” to make a poison, and it is the victim who translates the codes.

“Complicated by necrosis” elicits only the vaguest judgment call—what seems to be implied is that the necrosis itself is the “complication.” Does the writer mean complicated by infection? Then treat the infection. Does he mean complicated by gangrene? Gangrene and venom necrosis are two completely different conditions and should be treated as such. Gangrene spreads, having an origin not in venom but in bacteria. Venom necrosis becomes rapidly inert—the venom that caused it will have already infiltrated the tissue well before the physician sees the case. Its activity is short, usually about 3 - 5 days (if not surgically tampered with), and by 17 - 20 days will be in remission. If the necrosis persists past this period it is not venom necrosis; it is either imitative (programmed by an altered chemical exchange from surrounding

cells), or anoxia stemming from secondary causes. My review of different types of necrosis (Figures 17 - 20) shows just how complex the presentation can be. Surgical management, if it is used at all, should proceed cautiously toward specific etiologies, and in writings on the subject, physicians should not be left to define these terms haphazardly, for themselves. A clear cut guide needs to be developed. In cases where days have elapsed before the patient has sought medical help, where antivenom has not been used (or after its use is no longer efficacious), or when poor first aid measures (such as tourniquets or cryotherapy) have been employed resulting in damage secondary to the venom, perhaps here and only here can invasive methods be indicated in snakebite—albeit as a last-ditch action. But the working physician, who may never have seen a snakebite before, will not have the least clue what “prompt surgical management” means when presented with a massively swollen extremity bubbling with bullae.

The recent case of an agricultural worker and part time snake hunter in Costa Rica, Miguel X, is a prime example of what not to do in a snakebite. Bitten by an adult bushmaster on the forearm, and although receiving prompt antivenom treatment (200 ml), Miguel had the misfortune to meet a good surgeon before escaping from the hospital. A fasciotomy was promptly performed, and thereafter some necrotic tissue was removed each day for one week from the muscle (pers. comm, A. Solórzano). Note, however, there was no skin necrosis in this case—all necrosis occurred in the clinically altered underlying fascia and muscle. Note also that even after the initial necrosis was removed, debridement continued on a daily basis as new necrosis developed. Not surprising in a gaping 9 x 16 cm crater cut to sub-facial depth, exposing muscle, tendon and bone during the early healing process! Here is a clear-cut case of necrosis amplified by surgery, enhancing anoxia and encouraging hemorrhage, additionally exposing the affected tissue to oxygen and bacteria. A year’s investment in split-skin grafts has not restored Miguel’s arm to normal appearances, nor is it likely that it will ever regain normal function. More tragic is a recent case in southeastern Peru (recorded in Mellor and Arvin, 1996) where early surgical tampering in what was probably not even a severe bite (my view, not the authors), led to the amputation of a man’s leg at the hip. Thousands of such mismanaged cases occur every year in Latin America, Asia, Africa, and even the United States—victims of “prompt surgical management.”

One doctor in Suriname told me he routinely performed fasciotomy in *every case* of snakebite, regardless of the severity, and this usually entailed excision of the bite area as well! How many mutilations had this one man performed in his lifetime on guileless patients who might have been better off trusting the local witchdoctor? Perhaps there is more sound advice to be had from America’s religious snake-handlers (who endure venomous snakebites on a regular basis and most without serious disability) than from physicians who, in this modern age, still practice such witchcraft routinely. A survey conducted on the entire five-state membership of the Pentecostal church might find less maimed individuals comparatively—people who scorn all hospital treatment, including antivenom. Ultimately, the responsibility must rest with those medical authors who persist in making claims for the success of surgery in spite of mounting evidence to the contrary, or who use hastily concocted or vague terminologies that provide no clear diagnostics for continuing this outmoded, damaging, and dangerous procedure.

The type of necrosis determines the type of treatment

This is a matter ignored by most if not all writers on snakebite. Yet its importance cannot be too strongly emphasized. Venom triggers various responses ending in necrosis, and different kinds of necrosis can be observed. In general, necrosis results from:

- (1) The primary necrotic agents of the venom. *Rare*
- (2) Hemorrhagic effects of the venom (recognizable by erythrocytic debris; this will appear blackish and hard). *Common*
- (3) Deficits in blood circulation (e.g., vasoconstriction), and this may be combined with either of the above conditions. *Rare*.
- (4) Tissue anoxia due to deficits of blood circulation caused invasive (e.g., surgical) or mechanical means; i.e., iatrogenic treatments (tourniquet, etc.). *Common*.
- (5) Secondary infection. *Common*.
- (6) Autoimmune reaction (delayed type hypersensitivity). *Rare*.

In severe envenomings by vipers probably some or even all of the above effects will be seen, although they should be minimized with prompt immunotherapy. Corrective surgery should be used only as a last resort, however. Hemorrhagic damage presents as a hard, fibrous scab and this material, though quite dead, should be left in place. It acts as a barrier to expanding necrosis and secondary infection. Necrosis has a tendency to follow behind surgery, thus each time more tissue is debrided more necrosis appears. By slow increments the surgeon's knife creeps up the limb—the “death by a thousand cuts” method of incremental amputation. Hemorrhagic necrosis, by far the most common form, increases with a weakened cellular wall, hence it will always bloom first at the site of an incision. A good way to give your patient a serious or even fatal infection is to promptly excise the inoculation area (or other tissues damaged by venom), eliminating a natural protective barrier to bacteria and weakening the tissue wall against further venom hemorrhage. If the patient has already presented with an infection, then it is likely that antivenom has not been given in time or has been given in low quantity, and surgery to deal with sepsis may be a matter of course. However, true venom necrosis is best dealt with non-invasively. Certain serious infections (such as gas gangrene) will probably require some invasive management regardless, realizing that too early debridement of envenomed tissue where it is not warranted may be laying the groundwork for a later infection that would not otherwise have occurred. An autoimmune reaction resulting in *catastrophic necrosis* gradually overtaking the entire extremity (resembling a heparin-induced thrombocytopenia) is usually secondary to invasive wound management. As this will always be complicated by infection, it is very difficult to differentiate. Delayed Type Hypersensitivity Reaction (DTHR) is characterized by swelling, redness, an influx of macrophages and the production of tumor necrosis factor (TNF) and interferon-g (IFN-g). This type of necrosis, resulting in a “spontaneous necrotizing fasciitis,” is diagnostically a false-positive, blamed on envenomation, but the later may be only one factor triggering the effect. Surgery enhances this condition rather than relieving it.

Is fasciotomy for you?

It is not in a snake's best interest to cause edema in the prey animal. A rodent too swollen to move might also be impossible to swallow! Moreover, if

edema served a digestive function it would not “work”—the prey would be dead before the swelling could take place. From this it can be deduced that venom did not evolve agents especially to cause edema; there is no reason for natural selection to retain these chemicals in the venomous repertoire. Edema, rather, is the victim's contribution, a *response* to toxins evolved for other purposes, developing only in those larger non-prey animals (like man) that survive long enough to exhibit this symptom.

The problem with edema is contextual; an “abnormality” appears and the physician tries to correct it. He fails to see that edema, in fact, is the most normal part of the envenomation and that if he did not see edema he should be observing a true abnormality—a sign, perhaps, of something even more gravely wrong with his patient's immune response. We should not think of venom as “causing” edema; rather, we should recognize that it is the body's own contribution to the envenoming. The body is *reacting* to the venom autopharmacologically, with edema as a protective strategy. Gross swelling is a purposeful mechanism evolved to dilute the mass of the venom with a yet greater mass, past the point where the venom can do fatal damage to the organism. Swelling performs a biologically useful role as a defense against tissue damage, serving to expand the cellular wall with sheer water mass and prevent concentration of the destructive substance at the envenomation site, as well as block its communication past these fluid barriers. Decrease the swelling prematurely and you will inadvertently increase this destructive concentration taking place.

There is not a single verifiable case of edema alone contributing to loss of limb in snakebite. On the contrary, the cases of mechanical means to decrease swelling (e.g., ice-water, fasciotomy, etc.) contributing to loss of limb are too numerous to recount.

The term “compartment syndrome” (the allegedly dangerous symptom which fasciotomy allegedly relieves) is so grossly under-defined as to have no therapeutic relationship with real-life situations and no meaning outside of a medical dictionary. Intended to describe a condition where edema becomes so intense as to compromise vascularization and constrict nerve tissue, it has instead become a clinical catchall for any severe swelling “causing pain on passive stretch, hypesthesia, tenseness of compartment and weakness.” Since all these symptoms are concomitant in snakebite, the diagnosis is muddled from the

onset. Compartment syndrome is a word game, and the methods used to test for it evolved from a mythical preconception about a never documented result, responding in a knee-jerk way with a never well comprehended traditional approach. “Compartment syndrome” might better be named the *we-don’t-know-syndrome*. When the surgeon responds with fasciotomy, it is simply because he observes a lot of swelling, thinks it’s “bad” and “doesn’t know” what else to do about it. Not a very safe proposition for the patient.

Medicine has a long history of iatrogenia and a lot of what has come down to us as “modern therapeutics” are only reactions against the ill-fated treatment methods of the past. Probably the idea of “compartment syndrome” in snakebite arose as a reaction to the widespread use of tourniquet constriction, and is a relic from the days when tourniquets were freely used even by doctors. What doctors blamed on swelling they might better have blamed on their own faulty treatments. To date edema has never yet been proven to result in any permanent damage that could not otherwise be attributed to the cytotoxic effects of the venom itself. Physicians still defend the use of fasciotomy on the basis of an apparent but never directly proven effect. Fasciotomy always results in greater deficit to the afflicted extremity than would otherwise have occurred without it.

Advice to physicians: *snakebite + surgery = infection (bacterial necrosis), tissue anoxia, delayed type hypersensitivity response (catastrophic necrosis), amputation, shock, death and/or the absolute certainty of some disfigurement and deficit*. Non-invasive medical management of snakebite (e.g., with drug therapy and other nonsurgical methods) offers increased chance of full recovery with no long term physical deficit or disfigurement.

Fasciotomy has no value in preventing or controlling necrosis (Russell, 1983). Its efficacy has never been proven (Dart, 1999). Its success has been justified by a false positive, justified by an unknown outcome. Performed primarily as a prophylactic measure, it persists because no evidence can ever be salvaged to show what might have happened had the procedure not been performed. The logic for fasciotomy is a logic by default. It endeavors to save the limb by correcting an averred “abnormality,” and ends up losing the limb and often the patient into the bargain. It adds trauma to an already traumatic situation and increases mortality through increasing hypovolemic

shock. It is a political exercise as much as a medical one. It is used because it satisfies the patient’s expectations of the physician to produce concrete action in the face of massive swelling and the physician’s need to satisfy his own legal liability.

Perhaps the use of fasciotomy in the modern day has more to do with malpractice insurance than science. It persists because physicians can be held accountable for treatments withheld (e.g., “the doctor has not done everything in his power”), and are held less in account for treatments given (e.g., “the doctor has done everything in his power”). By performing fasciotomy, he will be protected by the complexity of sequelae in an outcome that can never be positively determined against him. Consciously or unconsciously—he may fully believe in the efficacy of his actions—he acts less for the patient’s behalf than for his own. Thus, fasciotomy, without any clear evidence to support its use, persists in the medical literature as a viable treatment for snakebite. This butchery is widespread, being performed in almost every country in the world and in some regions as routinely as the use of antivenom itself! “Better safe than sorry” is the tag-line justifying it. Tragically, one is even more unsafe and far more sorry the moment Mister Surgeon enters the treatment room.

So long as fasciotomy is permitted in *any* cases, it will be used in *all* cases where swelling is severe. And swelling is always severe in genuine envenomings by viperid snakes and many elapids as well. Fasciotomy is routinely more damaging than the purported “compartment syndrome” it proposes to relieve. Fasciotomy always causes some deficit, whereas “compartment syndrome,” as so vaguely defined, has never yet been shown to cause *any* deficit in snakebite. Deficit caused by fasciotomy is a mathematical certainty. Deficit caused by a “compartment syndrome” is an unknown, a remote possibility at best. Hedging one’s bets against a mathematical certainty in favor of an unknown is bad medicine.

Fasciotomy may safely be put to rest along with the cruciform techniques of lancing and sucking bite wounds that have also persisted from prior centuries as a treatment for snakebite. Surgical debridement should never be conducted except to relieve infection (but only if that infection cannot be controlled by non-invasive means) and should not be performed solely to correct hemorrhagic venom necrosis.

I have endured edema so tense that even to twitch the skin was to cause it to split open; and yet I for all that, I would never even consider going under the knife in a snakebite. If I were asked when and by what diagnostics I would accept fasciotomy to treat one of my own envenomings, my reply would be simply this: only when I can no longer feel pain or touch in the extremity, when the limb has lost all response to neural responses and commands—when, in short, it has gone completely numb. I have never experienced this symptom, and I do not know anybody else who has either.

The origin of snakebite treatment: therapeutic exorcism?

Alien anthropologists landing for the first time in our frightened little world, and having no inherited fear of snakes as we do, might conclude that use of certain treatments in snakebite reflects a deeper cultural origin than that of a well-intended science. Crosscutting throughout human history, they might link our curative practices not to any provable success rate, but to a religious esoteric older than medicine itself. Certainly all diagnoses, and the actions taken, spring from the neurological (psychological, semantic, cultural, etc.) dispositions of the actors first, before they find their way into the medical room. We comply with certain traditional practices not because they are proved or provable, but because belief-inertia makes us incapable of resisting them. We take pills not because we need pills (although we may need them); we take them because we believe in them and expect to be given them, and to give them in turn. The correlation with pills and cures can range from zero to any figure you can imagine; but the correlation with our desire to both give pills and receive pills is 100 percent. The psychological need for some form of treatment will always dominate its curative effect.

We live in a world of false positives, medically prescribed and scientifically “proven.” Our success rate is higher than in ancient days, but a wild randomness has guided us here, through a series of magic tricks that work—sometimes—and sometimes do not. When they work, our magic is “good”; when they do not work, the “evil humors” were too strong. The healer’s art arose from shamanism, not Merck’s handbook, an art evolved from effects that seem magical to the patient, and hardly less so to its modern inheritors and practitioners, proudly parroting the spells

and incantations of other medicine-men before them. Over the ages, powerful correlations with chance have bequeathed our book-learned shaman a reductionist philosophy called “science” from which to draw (and exhibit) power, but the lots are still cast in the sand, and the entrails read, though they be our own entrails sometimes, explored for misguided cells rather than for misguided demons who do not belong there. Medicine arose from just such a wild randomness, a psychological slight of hand to make us forget our desperation when confronted with forces we could not overpower—and letting the witch doctor taking credit for our immune systems. In this game “he who rattles the bones loudest, wins.” Viewing snakebite treatment chiefly as the artistic expression of its practitioners, and secondly, from the psychological needs of the victim to receive a particular kind of treatment that favors his cultural/religious expectations, we find the doctor-patient relationship exists as a sort of devil’s bargain where two residual forces work hand in hand in the battle against a superstitious evil both doctor and patient commonly believe in. So long as both actors believe in the same devil, you have a sound business deal. The medical artist fulfills the expectations of the patient—he cannot stray very far and still have a happy customer. If it is better to do nothing at all, the doctor must yet do *something* because that is why the patient is there, to see something done. Snakebite treatment, which has not advanced significantly since the development of antivenom more than a hundred years ago, has developed no acceptable new-age placebo by which to work its special effects. We are past the stage where eating certain leaves or doing a certain dance will be believed in by the patient. Mere antivenom has ceased being exciting to the fast-talking interactions of modern technological salesmanship. More complex formulas, the more elaborate the better, win the day, and win the patient’s confidence. This has happened in all forms of medicine, which has become so technologically elitist—e.g., “ah, but *we* have the latest laser!”—that the Hippocratic Oath has been thrown out with the patient. The greatness of medical progress has been to make itself unaffordable to nearly everyone in America, a glorious state that the corporate money-powers, with their guns to the heads of our politicians, mean to export to the rest of the world as well. The history of snakebite treatment follows just such a dependency: a competitive technology that so early-on exceeded its own abilities to do anything new that it reaches back frequently into the ritual smoke it sprang from, out of sheer desperation to keep up with style. A treatment

that ought, at most, to cost a few hundred dollars in antivenom and fluids, now costs thousands of dollars in mind-boggling blood testing (to reassure us of what we already know, that there are clotting problems), unnecessary surgery, and all the rest, just to show us that our doctors are using the latest and the best. So snakebite treatment plods on, looking for something new to do, or be. One year you have an electric stun-gun, the next you have an “extractor”; even the antivenom is being monkeyed with, requiring gallons of it nowadays (e.g., CroFab) whereas a few vials worked just fine formerly. Rife with ritualized expressions, relics from the witch’s circle and the medicine tent, snakebite treatment continues to mystify both patient and practitioner alike, while physicians blindly ransack a grab-bag of never very successful materials and methods in the hope of keeping up with Doctor Jones. As of this moment, somewhere in the world, somebody’s foot or hand is being split open, cauterized, branded, frozen, strangled, slashed, rubbed with painful crystals, excised, electrocuted, or amputated straight away. One-sided affairs in which I am afraid the doctor is having all the fun, promoting an idea more religious than curative.

Why do the Judeo-Christian countries (where snakes are equated with evil) lean toward violent, aggressive treatment of snakebite, rather than toward the more passive approaches taken in tropical animistic societies where snakes hold more of a regenerative role in mythology, rather than an antagonistic one? Why does surgery appeal to the Western mind as a better alternative than say, eating special leaves and drawing poultices? Certainly the cure rate is not greater when antivenom is not used, and snakes are even more venomous in the tropics. Released from its apparent intent (which is to cure), what does the artistic expression of surgery (of all possible forms of treatment selected) represent to both the practitioner and his patient (who must give ultimate approval for its use)? Is it a subconscious need of the physicians to excise (read *exorcise*) the evil of the snake, abetted by the patient whose expectation is to see the evil excised? Does the method of treatment reflect the moral expectations of our society, an acceptable means of retribution against the serpent “whose evil spirit yet lives within the wound?” A recidivistic case of, *If thy right hand offends thee, cut it off—?* The patient contributes through his own tacit expectations, perhaps needing to be punished for his congress with the demon-snake (his blood diluted by the devil’s substance becomes spiritualized, a sin) with only the most

radical and violent ritual capable of expiating him. The cruciform brand of the old “cut and suck” method evolved from a more invocative than practical strategy; the carving of a *sacred cross* over the devil’s marks, to drive the demon out.

The Pentecostal snake-handlers do not require human intercession to banish their devils—they have a patriarchal God who asks only faith for His fee. But the scientific heathen abandoned in the techno-wilderness, must extract his cures from an increasingly material realm. Divorced from “divine contact,” and urged on by vague impulses no less beyond his understanding than those of his less enlightened forbearers, he digs frantically with his knife in order to banish the mysterious force of nature whose pharmacology both intrigues and horrifies him. His Gods arise and appear not in religious tracts, but in the equally dogmatic assertions of other scientists. Were our extra-terrestrial visitors Freudians as well as aliens they might diagnose other causes, such as those originating in childhood; a puerile curiosity to see what is inside so gruesome an item as a snake-bitten hand or foot, which, swelling up with fluid, becomes phallic; the gratification of taking complete license with the body of another person, of splitting end to end the monstrously swollen member and watching its insides avulse—a deeply personal activity between consenting parties, medically justified. Old demons die hard.

Literature Cited and Related Reading

- Beers, M. H., and R. Berkow. 1999. The Merck manual of diagnosis and therapy. Merck Research Laboratories. Whitehouse Station, N.J.
- Bjarnason, J. B., and J. W. Fox. 1994. Hemorrhagic metalloproteinases from snake venoms. *Pharmacol Ther* 62, 325-372.
- Blaylock, R.S. 2000. Antibacterial properties of KwaZulu Natal snake venom. *Toxicon*. 38:1529-34.
- Bogert, C. M. 1943. Dentitional phenomena in cobras and other elapids, with notes on adaptive modifications. *Bull. Am. Mus. Nat. Hist.* 81: 285-360.
- Bolaños, R. 1972. Toxicity of Costa Rican snake venoms for the white mouse. *Amer. Jour. Trop. Med. Hyg.* 21:360-363.

- Bolaños, R. 1982. Las serpientes venenosas de Centroamérica y el problema del ofidismo. Primera parte. Aspectos zoológicos, epidemiológicos y biomédicos. Rev. Costarr. Cienc. Méd. 3:165-184.
- Bolaños, R., G. Muñoz and L. Cerdas. 1978. Toxicidad, neutralización e inmunoelectroforesis de los venenos de *Lachesis muta* de Costa Rica y Colombia. Toxicon 16:295-300.
- Bolaños, R., O. Rojas and C. E. Ulloa Flores. 1982. Aspectos biomédicos de cuatro casos de mordedura de serpiente por *Lachesis muta* (Ophidia: Viperidae) en Costa Rica. Rev. Biol. Trop. 30:53-58.
- Campbell, J. A. and E. D. Brodie, Jr. (eds.) 1992. Biology of the pitvipers. Tyler, Tex: Selva.
- Campbell, J. A. and W. W. Lamar. 1989. The venomous reptiles of Latin America. Ithaca, NY: Cornell University Press.
- Cedergren, E, Johansson, B., Heilbronn, E., and Widlund, L. 1973. Ultrastructural analysis of phospholipase A induced changes in membranes of synaptic regions in rat motor cortex. Ex. Brain Res., 16:400.
- Damico, D. C., S. Lilla, G. de Nucci, L. A. Ponce-Soto, F. V. Winck, J. C. Novello, and S. Marangoni. (2005). Biochemical and enzymatic characterization of two basic Asp49 phospholipase A2 isoforms from *Lachesis muta muta* (Surucucu) venom. Biochim Biophys Acta 1726, 75-86.
- Dart, R. C., J. T. McNally, D. W. Spaite and R. Gustafson. 1992. The sequelae of pitviper poisoning in the United States. In: Biology of the Pitvipers, (eds.) J. A. Campbell and E.D. Brodie Jr. Tyler, Tex.: Selva.
- Dart, R. 1999. Int J Med Toxicol 1999; 2(1):1, Hall EL. Ann Emerg Med 2001;37:175-80).
- DaSilva, N. J., S. D. Aird, C. Seebart and I. I. Kaiser. 1989. A gyroxin analog from the venom of the bushmaster (*Lachesis muta muta*). Toxicon 27:763-771.
- Diniz, M. R., and E. B. Oliveira. (1992). Purification and properties of a kininogenin from the venom of *Lachesis muta* (bushmaster). Toxicon 30, 247-258.
- Ditmars, R. L. 1910. Reptiles of the world: Tortoises and turtles, crocodilians, lizards and snakes of the eastern and western hemispheres. NY: Sturgis and Walton Co.
- Esquerre, C. 1976. The minimum lethal dose (MLD) of venoms from Peruvian Crotalidae Snakes. San José, Costa Rica: Fifth international symposium on animal, plant, and microbial toxins abstracts.
- Estep, K., T. Poole, C. W. Radcliffe, B. O'Connell and D. Chiszar. 1981. Distance traveled by mice (*Mus musculus*) after envenomation by prairie rattlesnakes (*Crotalus viridis*). Bull. Psychon. Soc. 18:108-110.
- Estevao-Costa, M. I., Diniz, C. R., Magalhaes, A., Markland, F. S., and Sanchez, E. F. 2000. Action of metalloproteinases mutalysin I and II on several components of the hemostatic and fibrinolytic systems. Thromb Res 99, 363-376.
- Fan, H. W., and J. L. Cardoso. 1995. Clinical toxicology of snake bites in South America. In: J. Meier and J. White, (eds.) Handbook of clinical toxicology and animal venoms and poisons. New York: CRC press.
- Faraci, F. M., M. A. Klotz, H. W. Shirer, A. Orr and J. W. Trank. 1980. Characteristics of bulbus cordis mechanoreceptors in the pond turtle *Pseudemys scripta elegans*. Trans. Kansas Academy of Sciences 83(1):132-1980.
- Felicori, L. F., C. T. Souza, D. T. Velarde, A. Magalhaes, A. P. Almeida, S. Figueiredo, M. Richardson, C. R. Diniz, and E. F. Sanchez. 2003. Kallikrein-like proteinase from bushmaster snake venom. Protein Expr Purif 30; 32-42.
- Feres, T., E. Frediani-Neto, TB Paiva. 1994. Mechanism of smooth muscle contraction and relaxation mediated by kinin receptor. Braz J Med Biol Res 27:1911-6.
- Fitch, H. S. 1981. Sexual size differences in reptiles. Miscellaneous Publications of the Museum of Natural History, University of Kansas 70:1-72.
- Fuly A.L., S. C. Elias, R.B. Zingali, J. A. Guimarães, and P. A. Melo. Myotoxic activity of an acid phospholipase A2 isolated from *Lachesis muta* (Bushmaster) snake venom Toxicon 2000; 38: 961-72
- Gutiérrez, J. M. 1995. Clinical toxicology of snakebite in Central America. In: J. Meier and J. White, (eds.), Handbook of clinical toxicology of animal venoms and poisons. New York: CRC Press.
- Gutiérrez, J. M. and F. Chaves. 1980. Efectos proteolítico, hemorrágico, y mionecrótico de los venenos de serpientes costarricenses de los géneros *Bothrops*, *Crotalus* y *Lachesis*. Toxicon 18:315-321.

- Gutiérrez, J. M., F. Chaves and R. Bolaños. 1980. Estudio comparativo de venenos de ejemplares recién nacidos y adultos de *Bothrops asper*. Rev. Biol. Trop. 28:341-351.
- Gutiérrez, J. M., F. Chaves and R. Bolaños. 1990. Ontogenetic changes in the venom of the snake *Lachesis muta stenophrys* (bushmaster) from Costa Rica. Toxicon 28:419-426.
- Gutiérrez, J. M., G. Rojas and L. Cerdas. 1987. Ability of a polyvalent antivenom to neutralize the venom of *Lachesis muta melanocephala*, a new Costa Rican subspecies of the bushmaster. Toxicon 25:713-720.
- Giovanni-De-Simone, S., A. S. Aguiar, A. R. Gimenez, K. Novellino and R. S. de Moura. 1997. Purification, properties and N-terminal amino acid sequence of kallikrein-like enzymes from the venom of *Lachesis muta rhombeata*. J. Protein Chem. 16(8):809-818.
- Hardy, D. L., Sr. 1992. A review of first aid measures for pitviper bite in North America, with an appraisal of the Extractor (TM) and stun gun electroshock. In: J. A. Campbell and E. D. Brodie Jr. (eds.), Biology of the pitvipers. 405 - 14 Tyler. Tex.: Selva.
- Hardy, D. L., Sr. 1968. Male-male copulation in captive Mojave rattlesnakes (*Crotalus scutulatus*). Bull. Chicago Herp. Soc. 33(12):258-262.
- Hardy, D. L., Sr. and J. Silva Haad. 1998. A review of venom toxinology and epidemiology of envenoming of the bushmaster (*Lachesis*) with report of a fatal bite. Bull. Chicago Herp. Soc. 33(6):113-123.
- Hayes, W. K. and J. G. Galusha. 1984. Effects of rattlesnake envenomation upon mobility of male wild and laboratory mice. Bull. Maryland Herp. Soc. 20:135-144.
- Huang, M. Z., P. Gopalakrishnakone, M. C. Chung, and R. M. Kini. 1997. Complete amino acid sequence of an acidic, cardiotoxic phospholipase A2 from the venom of *Ophiophagus hannah* (King Cobra): a novel cobra venom enzyme with "pancreatic loop". Arch Biochem Biophys 338, 150-156.
- Hulin., A., Ochoa and J. M. Desbordes. 1982. Envenimations par des crotalides en Guyane Francaise. Med. D'Afrique Noire 29:249- 225.
- Kini, R. M., and Evans, H. J., 1992. Structural domains in venom proteins: evidence that metalloproteinases and nonenzymatic platelet aggregation inhibitors (disintegrins) from snake venoms are derived by proteolysis from a common precursor. Toxicon 30, 265-293.
- Kondo, H., S. Kondo, S. Sadahiro, K. Yamauchi, A. Ohsaka, R. Murata. 1972. Estimation by a new method of the amount of venom ejected by a single bite of *Trimeresurus* species. Japan. J. Med. Sci. Biol. 25:123-131.
- Lucus, S. M., and Jurg Meier. 1995. The biology and distribution of spiders of medical importance. In: J. Meier and J. White, (eds.), Handbook of clinical toxicology of animal venoms and poisons. New York: CRC Press.
- Madsen, T. and R. Shine. 1992. A rapid, sexually-selected shift in mean body size in a population of snakes. Evolution. 46:1220-1224.
- Magalhaes, A. and C.R. Diniz. 1979. Purification and partial characterization of the thrombin-like enzyme from the venom of *Lachesis muta noctivaga*. Toxicon 17, Suppl. No. 1:112.
- Magalhaes, A., R. N. Ferreira, M. Richardson, S. Gontijo, A. Yarleque, H. P. B. Magalhaes, C. Bloch, E. F. Sanchez. 2003. Coagulant thrombin-like enzymes from the venoms of Brazilian and Peruvian bushmaster (*Lachesis muta muta*) snakes. Comparative Biochemistry and Physiology Part B 136:255-266.
- Marsh, N.E., B. C. Whaler. 1984. The Gaboon viper (*Bitis gabonica*); its biology, venom components and toxinology. Toxicon 22 (5):669-94
- Mellor, N. H. and J. C. Arvin. 1996. Case report. A bushmaster bite during a birding expedition in lowland southeastern Peru. Wildn. Environmental. Med. 3:236-240.
- Milani Junior R, MT Jorge, FP de Campos, FP Martins, A Bousso, JL Cardoso, LA Ribeiro, HW Fan, FO Franca, IS Sano-Martins, D Cardoso, C Ide Fernandez, JC Fernandes, VL Aldred, MP Sandoval, G Puerto, RD Theakston and DA Warrell. 1997. Snake bites by the jararacucu (*Bothrops jararacussu*): clinicopathological studies of 29 proven cases in Sao Paulo State, Brazil. QJM, Vol 90, Issue 5 323-334, Oxford University Press.
- Minton, S. A. Jr. and M. R. Minton. 1969. Venomous reptiles. New York: Scribner.
- Mitchell, S. W. 1860. Researches upon the venom of the rattlesnake. Smithson. Contrib. Knowledge 1860:1-139.

- Pough, F. H. and J. D. Groves. 1983. Specialization of the body form and food habits of snakes. *Am. Zool.* 23:443-454.
- Reid, H. A. 1976. Venoms and Antivenoms. (Review on Glass, T. G. Jr. Early debridement in pitviper bites. *J.A.M.A.*, 235:2513, 1976). *Abstracts on Hygiene* 51:1139.
- Ripa, D. 1994. Reproduction of the Central American bushmaster (*Lachesis muta stenophrys*) and the black-headed bushmaster (*Lachesis muta melanocephala*) for the first time in captivity. *Bull. Chicago Herp. Soc.* 29(8):165-183.
- Ripa, D. 1997. Range extension for *Bothrops leucurus*. *Bull. Chicago Herp. Soc.* 32(2):25-26.
- Ripa, D. 1999. Keys to understanding the bushmasters (Genus *Lachesis* Daudin, 1803). *Bull. Chicago Herp. Soc.* 34(3):45-92.
- Rosenfeld, G. 1971. Symptomatology, pathology, and treatment of snake bite in South America. Pp. 345-383. In: W. Bucherl and E. E. Buckley, (eds.), *Venomous animals and their venoms*. Vol. 2. New York: Academic Press.
- Rucavado, A., E. Flores Sanchez, A. Franceschi, A. Magalhaes, J. M. Gutierrez. 1999. Characterization of the local tissue damage induced by LHF-II, a metalloproteinase with weak hemorrhagic activity isolated from *Lachesis muta muta* snake venom. *Toxicon* 37:1297-1312.
- Russell, F. E. 1983. Snake venom poisoning. Greatneck, NY: Scholium International.
- Sanchez, E. F., T. V. Freitas, D. L. Ferreira-Alve, D. T. Valverde, M. R. Diniz, M. N. Cordeiro, G. Agostini-Cotta, C. R. Diniz. 1992. Biological activities of venoms from South American snakes. *Toxicon* 30:95-103.
- Sanchez, E. F., C. I. Santos, A. Magalhaes, C. R. Diniz, S. Figueiredo, J. Gilroy, M. Richardson. 2000. Isolation of Proteinase with Plasminogen-Activating Activity from *Lachesis muta muta* (Bushmaster) Snake Venom. *Archives of Biochemistry and Biophysics*. Vol. 378, No. 1: 131-141
- Silva Haad, J. L. 1980/1981. Accidentes humanos por las serpientes de los generos *Bothrops* y *Lachesis*. *Mem. Inst. Butantan* 44/45:403-423.
- Silva, L. M., C. R. Diniz and A. Magalhaes. 1985. Purification and partial characterization of an arginine ester hydrolase from the venom of the bushmaster snake, *Lachesis muta noctivaga*. *Toxicon* 23(4): 707 - 718.
- Solórzano, A. and L. Cerdas. 1986. A new subspecies of the bushmaster, *Lachesis muta*, from southeastern Costa Rica. *J. Herpetology* 20(3):463-466.
- Solórzano, A. and L. Cerdas. 1989. Reproductive biology and distribution of the terciopelo, *Bothrops asper* Garman (Serpentes: Viperidae) in Costa Rica. *Herpetologica*. 45(4):444-450.
- Solórzano-López, A., M. Santana and H. W. Greene. 1987. Reproductive biology of *Lachesis muta stenophrys* (Serpentes: Viperidae) in Costa Rica. *Abst. Jt. Ann. Mtg. SSAR Herpet. League* :146.
- Taylor, E. H. 1951. A brief review of the snakes of Costa Rica. *Univ. Kansas Sci. Bull.* 34:1-188.
- Thomas, R. G. and F. H. Pough. 1979. The effect of rattlesnake venom on digestion of prey. *Toxicon* 17:221-228.
- Torres, J. R., M. A. Torres and M. A. Arroyo-Parejo. 1995. Coagulation disorders in bushmaster envenomation. [Letter] *Lancet* 346:449-450.
- Vial, J. L. and J. M. Jiménez-Porrás. 1967. The ecogeography of the bushmaster, *Lachesis muta*, in Central America. *American Midland Naturalist*. 78:182-187.
- Watt, G. 1989. Snakebite treatment and first aid. In: J. Campbell and W. W. Lamar (eds.), *The venomous reptiles of Latin America*. Ithaca NY: Cornell University Press.
- White, J. 1995. Clinical toxicology of snake bite in Australia and New Guinea. In: J. Meier and J. White, (eds.) *Handbook of clinical toxicology and animal venoms and poisons*. New York: CRC press.
- Yarleque, A. S. Campos, E. Escobar, F. Lazo, N. Sanchez, S. Hyslop, N. A. Marsh, P. J. Butterworth and R. G. Price. 1989. Isolation and characterization of a fibrinogen-clotting enzyme from venom of the snake *Lachesis muta muta* (Peruvian bushmaster). *Toxicon* 27(11):1189-1197.