

Occasional Papers of the Cape Fear Serpentarium
Death in the garden of good and evil
Six new cases of bushmaster envenoming*

by Dean Ripa © 2003



Figure 5. At even 9-months age a bushmaster has enormous fangs! A finger could be pieced through, with intramuscular injection a near certainty in a hand or foot. Photo Regina Ripa. Cape Fear Serpentarium.

He is a fool who injures himself by amassing things. And no one knows why people cannot help but do it. — Danse Macabre

If you are bitten by this snake, it is better to just lie down under a tree and rest for you will soon be dead. — Unknown, attributed to an Amazonian Indian tribe.

“IF YOU HAVEN’T BEEN BITTEN by a venomous snake, you aren’t handling them enough,” as master venom-extractor, Jim Harrison, puts it, fang-in-cheek. Truer words never mocked a man, as the followers of George Went Hensley—fingers black and bloating—can testify, when the guileful Serpent, truest of all believers, proves stronger poison than their own merely human faith. Veteran snake keeper, Mike Goode, Curator of Reptiles at Ohio’s Columbus Zoo, broke Jim’s rule only to pay for it in the end. Managing thousands of venomous snakes in his lifetime, he

beat the Devil at his own game, and younger than I am now, passed away in his sleep of causes unrelated to herpetology. Call him wise and careful, I fairly think he missed his chance! Eric Brand was another wise handler, and Brad Warren and Tommy Spivey. All died young but not from snakebite, though they played in the poison. Given the option, would they not rather have chosen to add another interesting case report to the books? One of the greatest handlers I know is Scott McKenzie, still living. He is one of those charmed charmers who are taking no chances, or at least taking them in so discrete a way that the snakes don’t seem to notice their option. When the roll is called up yonder, will he be there, boasting his great skill and deriding my clumsiness? Or will he

* **To cite this article:** Ripa, Dean. 2003. Six New Cases of Bushmaster Envenoming, *in* The Bushmasters (Genus *Lachesis* Daudin, 1803) Morphology in Evolution and Behavior; 3rd Edition. Electronic book. Cape Fear Serpentarium. Wilmington, NC.



Figure 2. A 1-day-old neonate showing fangs, which are 7 mm long in this 46 cm long specimen. Subcutaneous envenoming by neonates should not be deadly to adult humans, despite intense pain and dramatic edema. Severity of envenoming is probably related to route, with the more serious intramuscular inoculation likely only in the digits (in bites by neonates). At age 2 months, however, the hatch-size is doubled, and here i.m. injection is possible. Case 4 reports an example producing very dramatic systemic effects, which could have led to death.

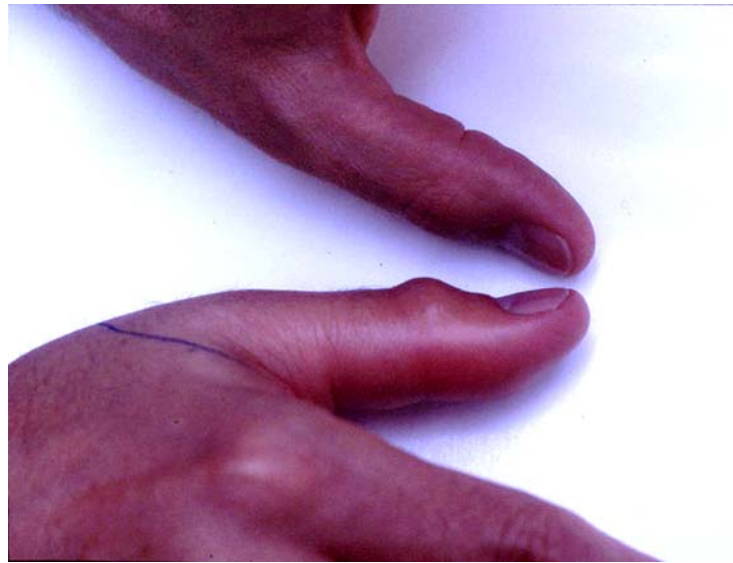sense a lack in his life's experience, long for the fiery throb he never had, the tang of blood in his mouth sucked from two oozing wounds, a blistered blown-up arm and the savor of hives brought on by excesses of antivenom? There is Charlie Jones and Carl Hiatt, George Tregembo and both his sons, old men now, who played in the poison and never knew the glory of its sting; but these angels of good judgement and better fortune are overall rare, and we can fairly guarantee that the Devil *would* have had His way with them, as He has had with me, if they had played a good deal more than on Sunday. Jim's maxim stands this side of heaven: handle the Devil enough and the Devil will have the last word! Caution is well for some—but what of *curiosity*? And when curiosity gets the better of caution . . . ? Perhaps only a Dewey Chafin can follow me into this dark tunnel of the soul, but there comes a moment when a special line is drawn in the mind—for the sheer purpose of exceeding it. Poe's *Imp of the Perverse* rules the game.

What does snakebite feel like? tempts the Serpent from his branch. One day it dawns on you, secretly, and with demented insistence, a need to *know*. I must have needed to know too much, too often. Eleven times I heard the call, and willingly answered! I had my little justifications to be sure—for every act of “clumsiness” one of those pretty, plausible stories making pardonable the not-so accidental “accidents” bubbling up through the muddy, unmentioned familiarity that breeds contempt. In truth I could not resist

the glare of Serpentism, the hypnotic, conflagrating Eye blazing down on me from the immortal Tree. A giddy ladder roped down from shuddering heights, shaped into the aspect of a snake, coiled moonbeams and nervous tissue. Transfixed, I climbed the branches, following a shining path into starstrung worlds winding and churning like wheels. A feathered tongue brushed my cheek and a poisonous fruit beckoned in the dark. I wanted to taste it—*willed* myself to taste it. Or *something* did. A trial by fire, and a test of—faith? *If not of faith, then of what???*

Snakebite is a poor hobby—and an even worse religion. It is a harrowing ordeal even for the seasoned “old hand.” Whether ten minutes from an emergency room or in a remote, mud-rilled jungle far from medical help, each experience brings a different level of panic, a different expectation of the outcome—each as grim as the reputation of the particular snake that has caused the bite. No amount of reassurance can put “the facts” from your mind, no painkiller lift the boiling fire from your limb. The poison that is transfiguring your flesh, blood, nerves, heart and brain (your pride, too!)—reshaping you for the slow ride to the mortuary *via* the faster ride in the ambulance—is giving you little glimpses into the suffering and debilitation to follow. Your mind casts back to the photographs you have seen of other victims like yourself, with whom you feel an unexpected kinship. The amputees dragging their rotten stumps around their yards didn't look so carefree, did they! Nor will you be, hooked up to a dialysis machine while a perplexed surgeon, peeling back putrid bandages, throws more and more hunks of you into the disposal till he has reached, after some unhappy months, an acceptable termination at your shoulder. It began much the same for the people in the photos. A feeling of “live fire germinating in the wound, as if red hot tongs contorted the flesh.” Picado's (1910) terrifying description of *Bothrops* bite remains as ac-

Figure 3. Minimal edema of thumb at 20 minutes post-bite in neonate Bite 1. Edema would increase over the next hours, surpassing the elbow. In bushmaster bite, severe systemic manifestations may precede extreme edema. If there is no swelling within 30 minutes of the bite, envenomation has probably not occurred. In this case, the damage remained local and no systemic effects developed.



curate as any written to date. The lividness and the deforming swelling as the black-blistered flesh explodes from the outward pressure; the mouth spitting up bloody threads; the unendurable pain and the eyes literally weeping blood; and finally, the awful sweat of “red pearls” signalling the end is near. For the professional snake handler there is the added irony of having been warned well ahead of time. Your sense of humor survives you, tugging on your i.v. line like a mocking old devil to remind you of your folly: “Play with snakes, would you! Well, we told you so! Why didn’t you listen?!” You wave your rotting arm in protest, mouth mucking through the blood, “I thoth them beauthiful!”

Indeed; and so might their venom be called beautiful, with its rich constellation of atoms, 2000 in all, in a molecular structure fundamentally the same as cancer. One needn’t always go so horribly. Cleopatra might have experienced only some mild discomfort from her cobra bite, until her eyelids began to droop, her speech slur and her lungs ceased responding to the mundane neural commands to breathe the sweltering Egyptian air. Some bites, especially the neurotoxic types, keep you guessing until the whole time. The victim doesn’t even know he’s has been poisoned until the saliva starts over-pouring his mouth and his breaths begins coming up short. There are the sly, creeping envenomings that kill you sneakily and unexpectedly (e.g., Joe Slowinski, *krait*; Carl Schmidt, *boomslang*; Robert Mertens, *twig snake*; the latter two species believed to have been only mildly venomous at the time); and there are those more grandiose poisonings that leave no doubt of their trajectory from ugly beginning to uglier end (Gerald de Bary, *puff adder*; Wesley Dickinson, *king cobra*; Douglas March, *fer-de-lance*). Finally, and most direly to be feared, are those envenomings that leave no time for the dark imagination to take hold. Envenomings so overwhelming, anguishing and sudden in their assault that the thought of death seems merely an abstraction, for it cannot be separated from the catastrophic physical attack—where the hope for survival becomes abandoned to a strange new quest: for a merciful oblivion. This is bushmaster bite, a roller-coaster ride straight down into

the Lake of Fire and that leaves little time even to pray. Of my 11 viper bites, three times in the field (in Africa and Central America) and seven times in the laboratory, four were by bushmasters.

Documented envenomings by bushmasters are so rare that my own four cases add significantly to the total number of bites recorded—almost 50 percent of all cases for which effects and treatment data are known (see Hardy and Silva, 1998, for a summary). These “interactive” bites (often called “illegitimate”) offer an insight into bushmaster envenomation not seen in other literature. For once, not only do we have an exact determination of the species (most “legitimate” bites are of questionable identification) but for the first time we know the exact size and age of the snakes, these being produced in captivity. We have also the exact localities of the lineage types. Two of these cases constitute the first described envenomings by *L. melanocephala* in the literature, while two others provide a firsthand look at the neonate bite, not yet recorded for any bushmaster species.

If bushmaster bite is rare, so is survival. These four new envenomings, with two more cases involving reptile enthusiasts, one in the State of New York (which I include here as “Bite 5”), and another in State of Michigan (Bite 6), are sufficient to skew the mortality statistics of Central American bushmaster bite (both species) from an uncomfortable 46% (5 of 11 treated cases; Hardy and Silva, 1998) to a slightly more bearable 37% (6 out of 16 cases). This in no way diminishes their severity. At least three of these six envenomings *would have been* fatal without immediate treatment, while one other (from a merely 2-month-old specimen) produced very dramatic symp-

toms that might well have been fatal to a smaller, less healthy individual. In the following passages I detail these envenomings with respect to symptoms and treatment, and show some support and some contradictions to the present literature on the effects of bushmaster venom in man. As Greene (1997) notes: “[Bushmaster] bite is extremely serious, and yet accidents are so rare that we lack a clear picture of proper treatment.” It is hoped that these pages, showing examples where treatment was successful, will serve as a protocol for the treatment of future envenomings.

Bite 1

My first bushmaster bite occurred in July 1993. I was 36 years old and weighed 79 kg. The snake was a 10 to 14-day-old *L. stenophrys*, hatched in captivity. It was 45 cm in total length and weighed 80 grams. The parents of this snake were collected in the vicinity of Bribri, Province of Limon, Costa Rica.

A defense bite (as opposed to a feeding-response bite), it was the wound of a single fang only, and this behind the second joint of the thumb. Symptoms were marked from the first: intense burning-throbbing pain, with extreme localized inflammation, and swelling of the entire hand and wrist within 2 hours. Edema reached the elbow within 6 hours, remaining swollen for 7–10 days. The thumb and hand remained sore and stiff for about 30 days. No systemic effects were noted. Treatment consisted of 5 ampoules of antivenom (*Anti-Botropico*, *Crotalico*, *Laquesico*, produced by Instituto Clodomiro Picado, Costa Rica) injected intramuscularly, and bed rest. Although local symptoms progressed rapidly, at no point did I consider my life in danger. The decision to take antivenom was made on the basis of significant local pain and the bushmaster’s reputation for causing serious tissue damage (a reputation I have since challenged). Recovery from my previous viperid envenomings seemed to indicate that rapid administration of antivenom could avert tissue damage, my not having sustained any permanent injury in these other accidents.

Gutiérrez et al. (1990) reports low edema and inflammation producing components in the neonate venom when injected into mice. And yet here was clear evidence of the capability of the venom of neonate bushmasters to produce significant pain, swelling and inflammation in a human being. To what ex-

tent antivenom prevented these effects becoming more severe can only be speculated.

On hindsight I would not have taken antivenom in this case. Use of antivenom increases sensitivity and thus limits the use of antivenom in future envenomings. I would experience similar encounters later on, and get by without any treatment. As there are times when only antivenom, and large quantities of it, can keep you alive, one wants to “save oneself” (pun unintended) for these grave eventualities, and not risk combining anaphylaxis, from allergic shock, with the already grave hypovolemic shock-effects that underscore a serious envenoming. The symptoms of a serious bushmaster bite are of quite unmistakable character and not to be confused with the comparatively mild sequelae seen on this occasion.

Bite 2

My next bite took place in the fall of 1994. The snake was a 1.4-year-old captive-born and raised *L. melanocephala*. Its length was 150 cm, and it weighed 2200 g. The lineage was vicinity of Rincon, Osa Peninsula, Costa Rica. A feeding response bite, the snake’s mouth closed across the knuckles and base of my ring finger, and then held firmly on for a few seconds, till my own violent resistance dislodged its grip and the snake let go. There was considerable blood from the fang wounds, and stinging.

Despite the full embedding of one 2 cm long fang into the tendinous area immediately behind the knuckles (the other penetrating to a superficial depth in the web of the middle fingers), the bite produced little more than local pain, a swollen hand and forearm (not surpassing the elbow), and a month or so of “stiff and sore” fingers. I declined antivenom, and, two hours after the bite, went out and had a good supper. I recall that I remained passionate enough that night (and careless enough of my health!), to fulfill the sexual obligations to my then newly-wed wife; these maneuvers were unimpaired. Obviously I did not consider my life in danger, and while the pain was gnawing and troublesome, it was not enough to dissuade me from pursuing such carefree and vigorous physical activity, doubtless encouraged by the cannabis I has smoked earlier. Other than the lurking fear of some possible intraorganal complications in store later on (e.g., Karl Schmidt’s fatal boomslang bite, with its long delay), and a periodically rapid and dunning heartbeat (that had nothing to do with sex!), no sys-

temic effects were detectable. There resulted no bleb formations or other hemorrhage, abscesses or necrosis. Ultimately, there was not even much swelling, which remained mild and receded completely after three days. A mild lymphadenitis persisted for a week or so. Here was a potential for life-threatening effects from a fair-sized, subadult snake with a definite intent upon killing prey, and yet clearly not much venom was injected—a dry, or at least “dryish” bite. Witnessing the accident was my wife, Michelle Ready, an Australian national who knew very little about envenomation and nothing whatever about the reputations of the New World snakes. Amazed at how I seemed to just walk through the affair, she remarked afterwards that “bushmasters must not be very poisonous.”

Bite 3

The events of April 17, 1995 generously refuted my wife’s comments. In a feeding response, a 120 cm long *L. melanocephala* (9-10 months old; same lineage as previous) struck the dorso-ulnar part of my right hand and wrist, and gave what I recognized within seconds to be a serious envenoming. Pain was immediate and stunning, and spread rapidly throughout the hand, into the fingers, wrist and forearm. There was considerable bleeding from the deep puncture wounds (the fangs of a specimen this size are roughly 18 mm long). I took this bleeding to be a bad sign as there are two large brachial veins in that part of the hand. An attempt to bleed the wounds of their venom manually (under cold running water to prevent coagulation) expressed considerable blood at first, but, with the extreme depth of penetration, the advancing edema soon pressed the wounds closed. Within about two minutes no further blood could be expelled. Swelling up almost before my eyes, the skin (and underlying tissue—fascia, tendons, muscles, &c.) rapidly tightened and within 5 minutes I could no longer bend my fingers to make a fist. Local pain increased steadily and became transfixing—the muscles of my hand paralyzed, as it were, with a deep concussive ache like a combination of blunt trauma and fire burn, and that gripped me with each new throb of my intensifying pulse. Systemic effects were rapidly incapacitating:

At 10 minutes: dizziness, loss of coordination and balance resulting in an inability to stand; temporary losses of consciousness; altered sensorium (visions of hallucinogenic

color patterns, sense of enlarged surrounding space); drowsiness with feelings of euphoria.

At 15 minutes: nausea; sweating and cool skin; feeling of swollen tongue (making speech difficult); numbing of lips accompanied by uncontrolled drooling/alternately dry mouth and difficulty swallowing; lymphadenitis; rapid pulse (rising to above 110).

At 20 minutes: projectile vomiting; explosive diarrhea; increasingly rapid pulse (to 125); lowered blood pressure (91 x 54 mm hg).

At 25 minutes: chills; intense stabbing pains in upper abdomen-lower chest; burning pains in kidneys (lower back) and violent cramping in the muscles of the lower back; hyperpnoea (abnormally rapid breathing); falling blood pressure (67 x 51 mm hg); rising pulse (130).

At 30 minutes: continued stabbing pains in abdominal-lower chest and lower back pain (becoming more severe); continued vomiting and diarrhea; cold ashen skin; labored breathing; blood pressure continuing to fall (48 x 35 mm hg).

At 35 minutes: blood pressure nearly undetectable; pulse faint; respiratory distress; acrocyanosis (cyanosis of the feet); red and white spots on face, neck and chest; general body numbness; inability to sit up or stand; speech difficult.

At 40 minutes: No detectable blood pressure, absent pulse. Conscious but disinterested in fate.

The speed with which the bite of this relatively small snake (scarcely one-fifth the mass of the adult it would eventually become) incapacitated a man my size is grave testimony to the bushmaster’s reputation as a quick killer of human beings. Suddenly the old reports of “death in ten minutes” came grimly, believably together, and I saw my life leaving me. Bushmaster bite can be compared to being struck by a car; one is literally “knocked-down” by the venom, and within minutes of the inoculation. There is no time for pondering destiny (“have I been seriously poisoned?”), none of the thought-provoking delay of most other snakes bites, where systemic effects progress slowly by comparison.

Numbing of the lips and face, dizziness, loss of coordination and lapses of consciousness occur in under ten minutes. Space seems altered and objects appear disproportionately far away. The tongue feels thick and the mouth overflows with saliva. Speech becomes difficult, and one mimics unintentionally the stupor of alcoholic inebriation. Before 20 minutes have passed, convulsive stabbing pains attack the abdominal area. The shocks are hard and relentless, impacting at intervals of 2 - 3 seconds. Now the mouth begins geysering vomit and the lower tract exploding with diarrhea. The whole digestive system seems turning inside out. Doubled over with spastic cramping, the victim cannot stand up to make it to the toilet and soils himself where he has fallen down. The crippling agony in the limb, the draining weakness, dizziness and delirium, the projectile vomiting and diarrhea, and the paralyzing jolts to the abdomen that frame all this, form a picture of despair impossible to reconcile with the state of mundane good health enjoyed just prior to the inoculation.*

I had been bitten by a creature I had brought forth from the egg. I had once held that egg in my hand, weighing it—like *fate*? It seemed a quaint irony now, part of a fleeting existence receding rapidly from me. The pounding in my wrist and hand reminded me but dimly why all this was happening, and yet so stunned

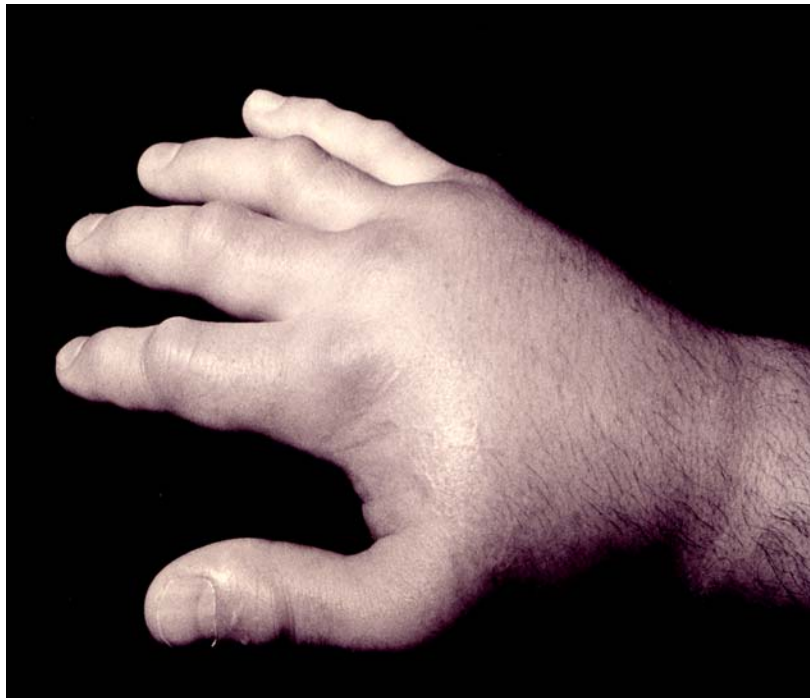was I that it seemed little to matter. A wrecked, wretched creature bathed in vomit and excrement, literally vibrating with abdominal seizures, I soon ceased struggling to help myself and remained lying where I had, as though ages ago, fallen down, my eyes staring in a blurred numbness, gasping through shrinking lungs. For all that, my mind remained clear and I was at all times aware what was happening to me. There was a sensation of falling, of being swallowed up within an irresistible darkness. I was sinking on a metabolic elevator, by droning and inexorable progression, further and further into the earth—down, *down* to some place even lower than where my body was. My blood pressure had abandoned me—in search of my lost pulse. By the inexorable logic of this strangest of poisonings, I was bleeding to death—without losing any blood.

From their report, the paramedics entered to find “a well developed 38-year-old white male lying outstretched on floor vomiting... wife says he has been bitten by a bushmaster snake... the fang wounds unbelievably far apart, approximately 3 cm.” And later: “Patient somewhat sedated but oriented times three, cooperative, and able to give pertinent information... wife said he needed epinephrine and Benadryl, with additional doses of antivenom intravenously... had

* It is almost equally shocking to the caretaker. Confronted by these life or death matters crashing in upon an apparent tranquility, witnessing in the human being an age-old pharmacological ritual normally staged on rats, and whose tide one is powerless to stem, one tries some basic first aid to avoid doing nothing at all: keeping the victim's feet elevated so as to force blood into his heart, and turning his head to one side to prevent him choking on his own profuse regurgitations.

The victim is responsive, but disinclined to speak. It seems to cost him great physical effort to move the muscles of the mouth and form words. Having learned by now that movement triggers more agonal spasms, he has been lying renitently still. Only the convulsive clenching of his abdomen, giving him a jerking, shivering appearance as he hovers prone upon his back, his mouth periodically opening like a trap to spout vomit, then closing mechanically once more, betray signs of an intermittent, feverish activity; but what began at first as a desperate measure to obtain comfort has evolved into a progressive muscular stiffness impossible to resist. A deep rigidity spreading up from his arms and legs, afflicting the torso, neck and jaws, has ended in his chest growing inelastic and tight. The deep heaving inhalations of breath that came formerly at quick intervals, one on top of another, have fallen to a gasping shallowness, no less rapid, but useless for gaining air. He labors to inflate his chest, but the minimal ventilation he receives does not compensate the difficult effort. His breathing is compartmentalized, concentrated within a small area in the uppermost part of his lungs. The extremities are blue, cyanotic. His neck and shoulders are covered with leprous white patches. He is incontinent and filthy, but is no longer concerned. Disconnected from his senses, he feels his body getting smaller and smaller, taking up less and less space inside a larger, colder emptiness that is welcome for being relatively painless. The clenching pains in the abdomen have not ceased, but are retreating farther away from a central point of awareness, as though they were happening to somebody else. His mind has turned inward. If he is conscious at all of people's efforts to save him, it is of the pointlessness of their operations, which he suspects must certainly fail. He no longer feels a sense of panic, rather a sense of detachment from the outcome. As hypothermia sets in, his torments grow vague and distant, gray as the feeling of utter cold invading his limbs. A glance at his face will show his eyelids slightly parted, his pupils tensely upturned, his eyeballs rolling back in his head. If questioned now as to how he is feeling, he will probably not bother responding. He is lying in a vast numbing wind.

Figure 4. Dean Ripa’s bloated hand 48 hours after near fatal envenoming by *L. melanocephala* (Bite 3). Tense edema exceeded the shoulder and skin appeared near bursting in the fingers, hand, wrist and forearm. (Ripa’s comparatively slender hand as it normally appears can be seen in Figure 17.) Within 7 minutes he was experiencing loss of consciousness; within 20 minutes projectile vomiting and uncontrollable diarrhea; within 25 minutes severe abdominal and chest pains; at 30 minutes total physical collapse; at 40 minutes no detectable blood pressure or pulse. The local sensations may be compared to a trauma injury (“like having your hand slammed in a car door”). The lethal action of bushmaster bite is primarily an effect on blood pressure: the victim dies from hypotensive shock. In Ripa’s four reported bushmaster envenomings (five as this chapter goes to press), two in the severe category, no bleb formation or necrosis occurred, and healed without any permanent defect.



taken nine vials intramuscularly before calling EMS....”

Actually, my wife called EMS—I would have been incapable of holding a telephone. Significant was a general body numbness as she plunged a stout, 20 gauge syringe-needle, of the type used for injecting horses, into my hips repeatedly, delivering the 9 ampoules of antivenom in voluminous bursts. “Okay, you can start now,” I told her, readying myself for the jabs. In fact she had finished minutes before. The crashing pain in my hand and arm, the delirium and fleeting losses of perception, were enough apparently to divert my attention from so mere a thing as a big needle crudely jabbed into me 9 times by hit-or-miss methods and delivering a massive 10 ml of liquid at each go.

The sheer size of the snake’s fangs with their deep intramuscular penetration would be jarring enough even without venom—with venom the pain becomes so transfixing that one is unable to think of anything else. As the venom spreads the limb becomes a boiling cauldron. A seething pressure as of some hot, corrosive liquid foaming chemically to life, fulminates within the tendons, and exerts such a tightness internally that the flesh threatens to explode. The knuckles erect like bubbles, the webs of the fingers disappear, and the thumb bulges into an ungainly stump. Before two hours have passed, the hand will have been converted into something resembling a cow’s udder, the digits absorbed into a gnarling, agglomer-

ated mass. Within minutes, however, the limb becomes disabled. The fingers, paralyzed with pain, grow so thick as to be inoperable. The underlying fascia of the arm becomes a terrible girdle macerating the blood flow and the skin itself becomes a constricting tourniquet. Pain is an important diagnostic sign. Because of the very long and stout fangs, there can be no “non-painful” bushmaster bites, so differentiating between a “dry bite” and a genuine envenoming is primarily a matter of determining the level of pain experienced. Discomfort being enhanced tenfold by the radiating effects of the poison, pain excruciating enough to hinder the function of the extremity is a good indicator of a serious bite, while swelling and inflammation are so dramatic as to leave no doubt. As shock sets in, convulsive jolts to the abdominal muscles send one crashing to one’s knees. The jolts spread, soon involving the lower back as well. With all these writhing interventions, medically treating oneself is impossible. The limb bangles about like a useless club, the bowels are discharging uncontrollably and one can’t stop retching long enough even to consider elementary first aid. So complex a process as self-administering antivenom is out of the question. One needs assistance even to reach the toilet. Soon even this sanitary ritual is abandoned as the need to lie prone becomes overwhelming. A human sewer disgorging enormities of vomit and excreta, one flops indifferently down in one’s own purgations, the will to survive reduced to a distant, unbelievable idea. The conflagration in the wound is sufficient to bring one to tears, and yet it remains the least memorable of the process. I re-

member my wife lifting up my turgid hand and arm onto a pillow at my side, on the floor where I lay stripped of my shitty clothes; and then her asking me, in a sobbing voice, if there was something she could do to make me more comfortable. “Make the little man stop,” I mumbled in my delirium. “What little man?” she questioned. He was my own private nightmare no-one could see but whose fists I plainly feel, detonating against the muscles of my stomach—a phantom pugilist adhered to my chest like the snarling imp in Fuseli’s *The Incubus*.

Systemic effects continued en route to hospital and some four hours more while in emergency care. I vomited over myself and lost control of my bowels many times while on the table. Literally vibrating from the fasciculations of the abdomen, my teeth chattering incessantly (I felt freezing cold), I struggled to keep a clear enough mind-set to direct from my bedridden position the course of treatment that I suspected might save me. The attending physicians, who had seen few cases of snakebite and certainly none like this one, followed my feebly expressed instructions and, combined with their own professional expertise, soon arrived at a protocol: intravenous normal saline with epinephrine drip (to control hypotension), 200 mg of diphenhydramine, 125 mg methylprednisol, with an additional 50 ml polyvalent antivenom intravenously (*Anti-Botropico, Crotalico, Laquesico*, produced by Instituto Clodomiro Picado, Costa Rica). The latter now totaled 14 ampoules. Oxygen was continued (started en route to hospital). Prothrombin time was moderately abnormal. Myoglobin and fresh-frozen plasma, and 20 mg. phytonadione were given to help restore normal fibrinogen, which was markedly reduced. At no point, however, were hemostatic abnormalities visible to the eye. No blistering or bullae, no mucosal bleeding (epistaxis, hematuria, etc.) were seen, and even the fang wounds produced little discharge. Some minimal extravasation later was probably the result of the intense pressure from the swelling rather than any increased capillary permeability or coagulopathy. Over the next 3 hours blood pressure was gradually elevated and most abdominal-chest pain ceased. After 5 hours blood pressure was normotensive. Meperidine (75 mg) helped with local pain, which remained severe.

Despite antivenom, edema of the hand and arm advanced, becoming massive over the next 48 hours. By 60 hours edema had exceeded the shoulder, encompassing the armpit, neck, upper chest and back. The arm remained tensely swollen for three weeks,

while the hand remained swollen for four weeks. Axillary lymphadenitis persisted for some six weeks. Petechiae and ecchymoses of the hand, wrist, forearm, upper arm and axilla evolved over 48 h to 100 h, but this was mild and appeared to be caused by edema rather than any hemorrhagic effects of the venom. No hemorrhagic bullae or skin necrosis developed. General recovery was slow and uneventful, however attended by great physical weakness. The fang punctures healed without scarring. The bite-site and surrounding ulnar area remained tender for the first year, and flexation of the hand was compromised for the first 6-10 weeks. However, no residual defect resulted, and full mobility of the hand and wrist was regained after about four months.

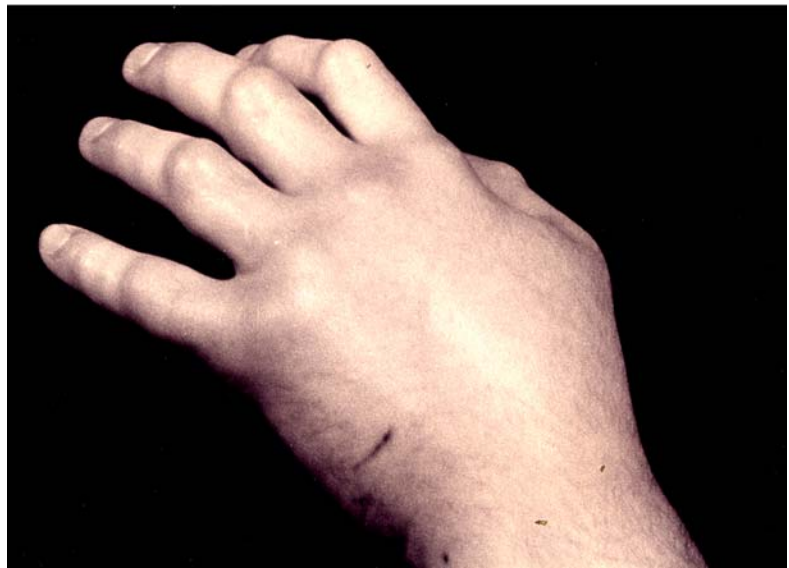The rapid systemic alterations seen in this case are a grim testimony to the severity of bites by these largest New World vipers. Quick arrival on the scene by EMS with early antivenom and prompt supportive therapy (within 1 h post envenoming) averted what seem destined for a fatal outcome.

Bite 4

Yet another firsthand opportunity to observe bushmaster envenoming occurred in November 1998. The fourth of my mishaps involved a neonate *L. stenophrys*, age 2 months (TL 57 cm; Wt. 110 g; lineage Bribri, Limon, Costa Rica). The bite occurred at 2:14 h while I was manually assisting the snake through an imperfect skin shed (I perform most work with these snakes during their nocturnal “waking” cycle). An angry “nuzzling” bite (see photo simulations in this chapter and Chapter 20), the snake inexplicably held on and had to be violently shaken off the finger.

Two 10 mm long fangs had penetrated the fleshy palmar surface of the middle joint of the right index finger, through the muscle to the depth of the bone. Based on past experience, I was instantly aware of having gotten another “bad one.” Searing pain occurred immediately, and with the tightening sensation of rapid swelling, was soon intensely throbbing, similar to having your finger crushed in a car door. There was considerable bleeding from the two fang wounds, revealing the depth of penetration to be considerable. I attempted manually to express as much blood from the wounds as possible in the hope of expelling some venom; however, as edema increased rapidly the wounds soon closed and further bleeding them became impossible.

Figure 5. Bite 3, showing receding edema after four weeks. Note fang wounds on the ulnar aspect of the hand and wrist. In this near-fatal case, the fang punctures did not necrotize, indicating that the hemorrhagic-necrotic properties of this venom are not deeply significant. Despite long-term edema, the skin remained clear. The principal dangers of Central American bushmaster bite are not local but systemic. Necrosis is probably the result of delayed treatment, secondary infection and/or confusion with bites by sympatric *Bothrops*. Note the great breadth of fang penetration in this species, one (the upper slash mark) on the side of the hand, and the other (the black dot at lower left) reaching the juncture of the wrist. Compare to the massive swelling in **Figure 1**, four weeks earlier.



This bite was extraordinary in that so small a snake, scarcely half the length of the example previously described (in Bite 3), and of dramatically smaller mass, produced comparably severe symptoms. Convulsive shocks of pain to the abdominal–lower chest area, vomiting and diarrhea, began within 20 minutes (after 50 minutes there was intense burning pain in the lower back/kidneys as well). Pulse rose to above 130, then later became faint and eventually nearly undetectable. Rapid breathing accompanied a feeling of constriction around the chest. Hypotension was again noted (63/50 mm hg at 30 min). Drowsiness, fever, chills, pallor and sweating, red spots on neck (flush), feeling of swollen tongue, alternating drooling and dry mouth, difficulty swallowing, cold skin, &c. At no point was consciousness lost, nor were there the color-hallucinations of the previous bite. While my senses remained clear, the violence of the illness left me mostly incapacitated and quite unable to help myself. Nevertheless I had periods of fleeting motor control and my sense of will was not entirely stolen from me by the pervasive weakness seen previously. Suspecting that administration of antivenom at this stage would only complicate the picture of what clearly represented a form of shock, and to avoid confusing symptoms with a possible autopharmacological reaction to the horse serum (the unusual symptomatology of the previous bite had left this question unanswered), I refrained from using antivenom this time and injected 50 mg diphenhydramine instead (frequent vomiting prevented retaining it orally). The antihistamine did little good. In treating serum sickness, which I have experienced several times, I have always noted that relief is prompt; but here nothing much seemed to

change. The antihistamine failing, I deduced that the form of shock I had was not purely histaminic; that is, it was not due to allergy. There followed three hours of agonizing convulsive pain in my upper abdomen and lower back, hyperpnoea (abnormally rapid breathing), and uncontrollable vomiting and diarrhea.

Other than some nausea and vomiting, by 5:50 h most of the systemic reactions had resolved, either spontaneously or from the eventual effects of the diphenhydramine. I felt myself improving. Local symptoms, however, continued to advance at a phenomenal rate: the bitten finger, hand and arm were now massively swollen and inflamed.

Swelling of the hand and arm gradually increased for the next 60 h. By 20 h post-venomation the swelling had surpassed the shoulder. The fingers and knuckles appeared near bursting, and great care had to be taken not to jar the hand (or to flex the fingers) lest the skin split open. The arm reached monstrous proportions and remained swollen to the shoulder for 14 days. After this time, the greater portion of the swelling in the upper arm began slowly shifting distally, back toward the elbow. As edema subsided, red streaks tracing the blood pathways extended from the wrist to the forearm and surpassed the elbow. After 25 days, the swelling in the hand and fingers had entirely resolved. The bitten digit, however, remained immensely swollen and of a strangely hard consistency for some 6 weeks. After four months the finger was still painful, stiff and indurate, and markedly hypertrophic, approximately one and a half times normal size. This thickness was probably deep scar tissue. After 8 months the enlargement became no-

ticeably reduced, and normal flexation was restored at about 1 year.

Noteworthy in this bite, as in the others, was the absence of hemorrhagic bullae and skin necrosis. Even the fang wounds ceased bleeding after a few minutes as the edema closed them. The mild ecchymosis that developed gradually over the course of days seemed rather the result of bruising from the massive swelling rather than from an induced coagulopathy or increased capillary vessel permeability.

This was an exceptionally “full bite” with complete embedding of both fangs and long hold-time. The fangs in a specimen of this size are about 10 mm in length—half the width of the finger—easily penetrating to intramuscular depth. Due to its strike-hold nature, a great deal of the snake’s available venom must have been injected in this bite for such rapid and extraordinary alterations to take place (Chapters 21 and 25 suggest probable amounts). Within 30 minutes the venom had completely overwhelmed an 80 kg man!

Recovery time was slow compared to the swifter recovery of the hand in Bite 3, where antivenom was used, suggesting that antivenom can have some effect in preventing local damage if used early on. Its absence in this case resulted in a long-term deficit.

Bite 5

In 1994, Bob Bowker, a reptile enthusiast in New York State, was bitten on the hand by a captive-hatched *L. stenophrys* I had supplied him a few months earlier. The snake was approximately 1.3 m long, weighed 1.8 kg, and was 1.4 years old at the time of the envenoming. It had been born at my facility from a lineage native to the vicinity of Bribri, Limon province, Costa Rica. Bowker, who was accustomed to working with the less heat-responsive elapids, was bitten while approaching the open cage with a warm damp towel he had been using to clean another cage. In the classic heat-pursuit attack (Chapter 20), the snake came lunging out of the cage and grabbed his hand.

Systemic alterations were rapid and extreme. Severe hypotension, absent pulse, and periods of unconsciousness occurred within 15-20 minutes. There was convulsive abdominal pain, uncontrollable vomiting and diarrhea. As there appeared not time enough

to reach a hospital by road, the critically ill patient was airlifted from his yard to a medical facility, where quick supportive treatment to restore blood pressure and 20 ampoules (200 ml) antivenom (Wyeth polyvalent, North and South American) saved his life.

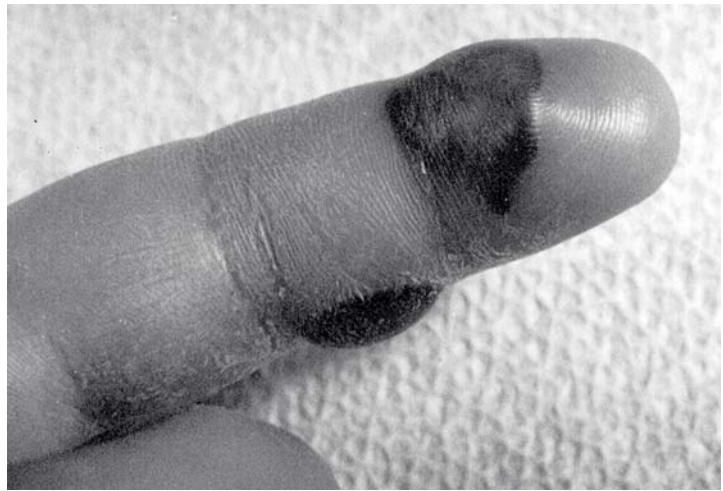
Here again we observe a near-fatal encounter with dramatic shock-like effects occurring within a very short time frame. Considering the evident severity of the symptoms, the lack of necrosis is remarkable. Bowker recovered without any lasting damage to the extremity. In his own words, “I have had worse tissue damage from the bite of a mere massasauga (*Sistrurus catenatus*). The sheer speed with which this venom affected my whole body was amazing. In less than half an hour I was dying!”

Bite 6.

The strangest of the interactive bites within my personal knowledge occurred in Commerce, Michigan. The symptoms were distinct from any yet seen. This envenoming involved yet another of my own captive-bred specimens, a large adult *L. melanocephala*. The snake was 2 meters in length, 9 years old and weighed at least 5 kg. The envenomee was Rodney Miller, 38 years old, healthy and of muscular build. He weighed 90 kg. I emphasize this fact, as he would weigh much less after his experience with the bushmaster.

Miller was attempting to remove a piece of a dry skin-shed that remained had adhered to the snake’s back when the snake, looping through a hollow-log decoration in the cage, turned and struck his hand. One fang penetrated the dorsal aspect of the right middle finger; the other fang producing only a laceration on the palmar aspect of the right index finger. The palmar wound seems not to have injected venom, while the dorsal one could not have been only incompletely embedded, owing to the shallow depth of the bone in that part of the digit. The fang length is 2.5 cm in a snake of the size that bit Miller. Nevertheless, it is clear that some venom must have been injected into the wound on the middle finger. Miller was admitted to the emergency department within 10 minutes of the envenoming. At this time the physicians noted his anxiousness but evident normalcy: “A regular heart rate, pupils equal and reactive to light, no erythema or exudate, no angioedema or swelling of the mouth, good muscular coordinations and mobility, with cranial nerves II-XII grossly intact. He denies any abdominal pain, nausea or vomiting. All he has is pain in his finger. His

Figure 6. Dean Ripa's charred looking index finger 10 days after bite by neonate *Bothrops asper* (Trinidad), showing hematomas (with bleb formation) where the skin had become so taut it "popped," resulting in venom necrosis. Blistering and swelling had decreased in size markedly by the time this picture was taken. The venom of this species is strongly hemorrhagic. It is in areas of hemorrhage that necrosis usually forms. No resemblance to bushmaster bite.

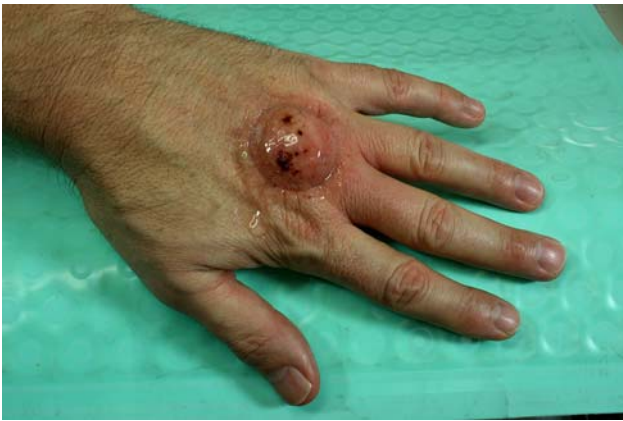
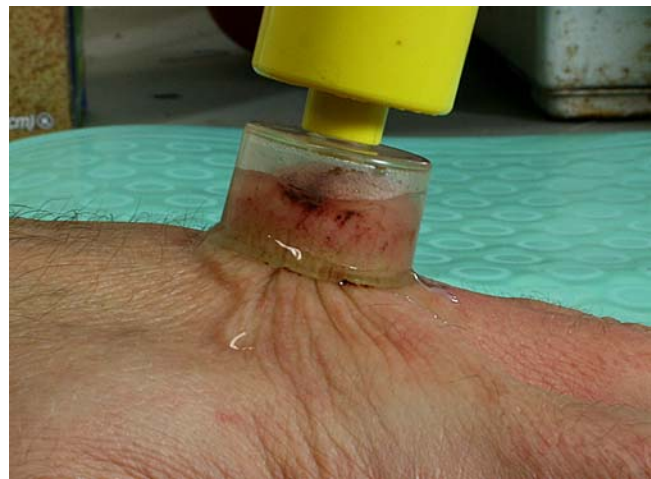
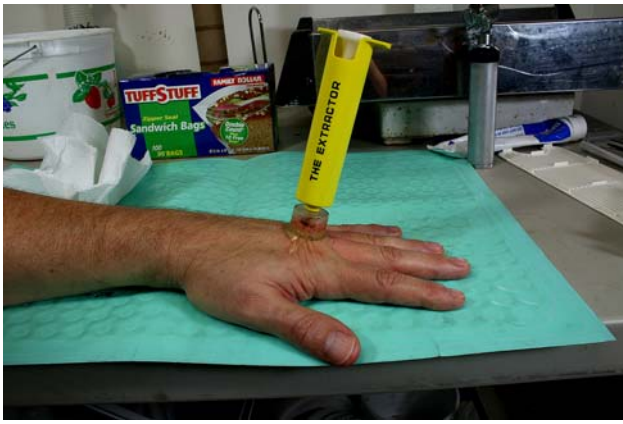pain is currently 8/10 in intensity. Blood pressure: 134/59. Pulse: 61. Respiration: 14." Severe pain is, of course, a reliable sign of envenoming in a pitviper bite. This was shortly to become much more intense. About 10 minutes after the examination the whole hand extremity began to hurt intensely, with a "feeling of fire all over his arm." Next he had a "violent reaction" of jolting pain in the abdominal area. His wife recalls him "rolling around in agony on the bed." His brother recalls him "curled up in a fetal position and shaking." These are strong suggestions of the "cattle prod syndrome," the feeling of abdominal shocks and jolts that resemble cramping but which are violently stronger. The fetal position makes them more bearable (pers. experience). His symptoms were now rapidly advancing, with profuse sweating and transfixing pain, a situation underlined by the aberrant constitution of his blood. From the treatment report: "Hemoglobin (Hgb) is 18.9, white blood cell count (WBC) is 14.9, and platelet count is 235,000. D-dimer is now markedly elevated at 28.69. Coagulation studies cannot actually be run because the patient's blood is not clotting. Two EKGs show there to be an incomplete bundle branch block but normal sinus rhythm. No ST elevation on either test. The patient is now having swelling of his face and tongue. He will be in danger of occluding his airway." He was given Benadryl, Solu-Medrol and Zantac via i.v., none of which had any effect on the swelling. Later: "The patient required intubation and was given 20 mg of Etomidate and 120 mg of succinylcholine and attempts to intubate the patient by myself have failed. Anesthesia came down to intubate the patient and place a 7.5 endotracheal tube. Prior to the anesthetist's try, the patient had an episode of emesis in which he may have aspirated some of the stomach contents." The patient and his brother recall episodes of vomiting prior to the intubation (pers. comm); but this is not listed in the report, which seems more concerned with blood work than with bedside observation. At this point it becomes difficult to piece the story together. The family was not allowed into the treatment room and the patient's own memory of events is impaired due to the heavy sedation necessary to control his intense pain.

The report notes that Versed (5 mg) brought no significant pain relief, nor did 4 mg of Ativan (which produces transient amnesia). After the Propofol was administered to assist the intubation, Miller became unresponsive—in short, in an induced coma. He would have no memory of the next 5 days—a period during which he would also experience respiratory failure. What his wife observed early on was his intense facial swelling, which became so profound as to make him unrecognizable. "I went in his room and did not know who he was."

The report continues: "He is now having worsening of the swelling of the hand. He shows signs of hemolysis and needs antivenin. We started reconstituting Wyeth polyvalent Crotalinae antivenin and prepared for infusion; we were having trouble maintaining peripheral access on him so I then installed a triple lumen central line in the right femoral vein." A subsequent hypotensive episode was presumed secondary to the propofol, but this improved after receiving i.v. fluids. "He also started having bleeding from the wound site as well as from the intratracheal tube which suggests he is going through mass edema from the envenomation. We spoke with the antivenom bank down in Florida who located genus-specific antivenin up in Toledo. We are currently facilitating transfer of the antivenin to the hospital. The patient will need to go to the ICU. Toxicology was notified and has been at bedside." The patient was admitted to ICU in critical condition.

A strange case. Two days after the bite, Miller's condition appeared grave. He still had severe swelling of the upper airway, mucosa and lips, enough to cause asphyxiation. His serum potassium was elevated (5.9 from 3.3 on admission) and his creatinine was high (1.8). He had poor clotting (e.g., fibrinogen

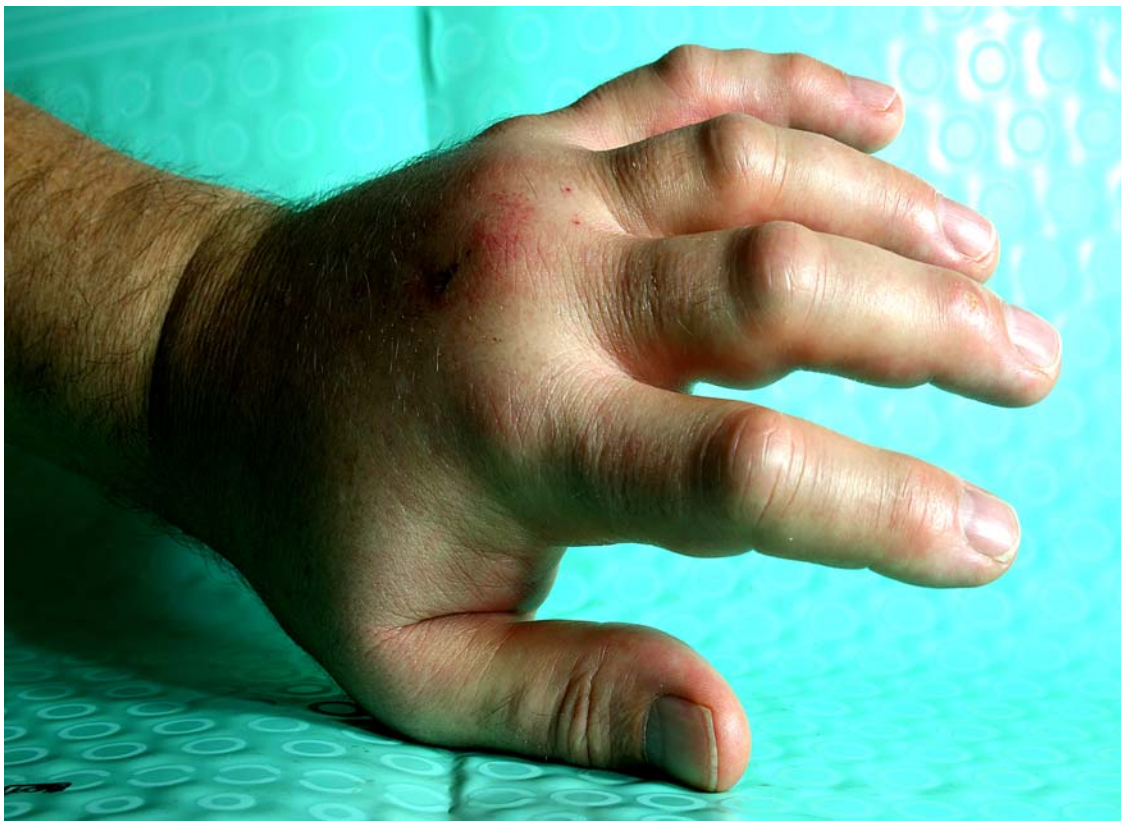
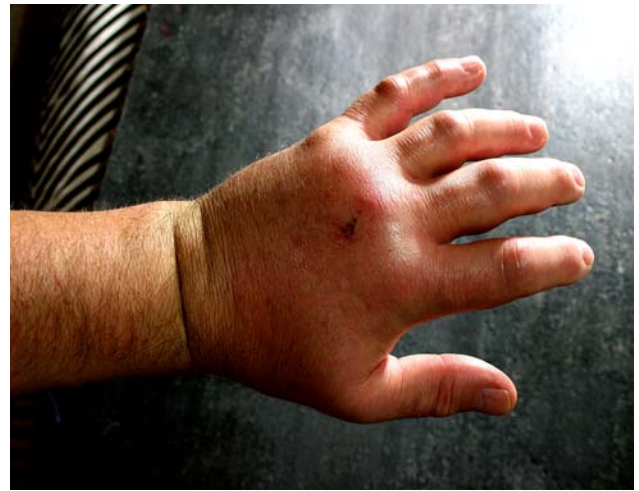
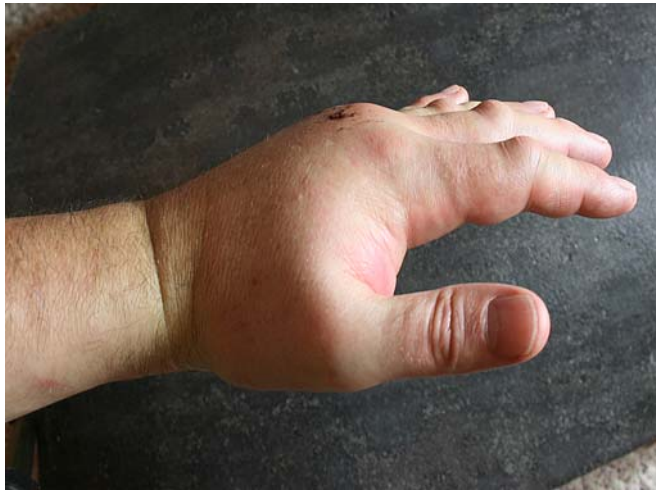Evolution of an envenoming

Ripa's fifth bite by a bushmaster occurred just at press time so it is not included in the original text. The culprit is a *L. muta muta* neonate, age 24 days, 18 inches long and weighing 74 grams (pictured in Chapter 6, Figure 8). Within ten minutes of the bite *The Extractor*TM was applied to observe its effects (**Figures 7 - 9**), if any, on removing venom.

Two punctures (**Figure 9**), 2 cm apart, mark the envenomation site, where the venom was probably subdermally injected. The Extractor could barely encompass both punctures, even in the bite of this baby snake. The Extractor did, however, produce significant suction as seen in **Figure 9**. Whether or not any venom was actually removed is unknown, but Ripa was impressed just the same. "Some small amount of blood and serum came out, which was more than I expected since swelling quickly constricts the punctures. If nothing else the Extractor gave me the *feeling* it could be helping, and with the panic of snakebite being what it is, that alone makes it worth the modest cost. It was fun to play with, a welcome diversion from the possibilities of dying."

Ripa's previous experience with bushmaster bite led him to believe that he would not soon be dying in any case. While pain was intense and considerable edema evolved over the next hours, he did not, within the allotted time frame he is familiar with, experience the grave and violently reactive sequelae of Bites 3 and 4 (as recorded in this chapter). This bite, he was nearly certain, had been delivered subcutaneously, so the venom should not enjoy the toxic boost of the intramuscular injections he had enjoyed previously. The deadly "L-syndrome," he theorized, should not then occur. He got pretty much what he expected he would get from so small a snake: a morbidly increased hand and arm, and acute local discomfort. His normally slender hand as seen in **Figures 7 and 9** was within two hours converted into a livid, grotesque balloon, **Figure 10**. **Figure 11** is at 3 hours, with swelling exceeding the wrist. **Figure 12** is at 6 hours, with swelling reaching the elbow. The taut, swollen fingers are unbendable, as though the hand were encased in a catcher's mitt. By 16 hours the edema has reached the biceps, and as of this writing it is still growing, with some tightness and tenderness being felt in the shoulder. No antivenom has been taken as of this hour. The ultimate results remain to be seen as this book now goes to press. —ED.



Exploding with venom

Tense edema is painful in itself, and the pressure produced by the constricting fascia can be such that the doctors, unfamiliar with the snakebite paradigm, will try to do something done about it, even if it means doing the worst thing possible—performing surgery on the bitten limb. “Better off to just back your car over it than to let a surgeon into the treatment room. It’s much cheaper and accomplishes the same thing.” Ripa’s dour views of surgery in snakebite are reviewed further in Chapter 23. While tense edema in bushmaster bite is a definite sign of envenoming, it is not by itself a sign of a life-threatening condition. Bites 3 and 4 in this chapter review those more dangerous systemic alterations. At 16 hours after the bite, the calm, somewhat sedated Mr Ripa remains confident that he will not meet “the little man” in this case. “The critical minimum of K-complex necessary to activate the *L-syndrome* was too small,” he speculates. “Probably got less than 5 mg.” —ED.

less than 50 with PT greater than 120, INR greater than 13.15, PTT greater than 200) and showed signs of bleeding through the intratracheal tube. This was concluded not to be from a mechanical injury (a chest X-ray confirmed good placement), but from tracheal bleeding due to massive edema and perhaps hemorrhage due to an activated clotting cascade (the puncture wounds on his hand were now freely bleeding). The tracheal swelling is curious. Swelling of the face and air passages has never been recorded in any bushmaster bite (see Chapter 24, Figure 27 for an instance in *Bothrops* bite), probably the most unusual symptom in this series. It was angioedemic, certainly, and autopharmacologically activated, due to bradykinin formation from the complex of kininogenin protease and kallikrein proteinase abundant in bushmaster venom (Chapter 26). It was probably not a strictly *allergic* response? The patient had no known allergies, had never been exposed before to bushmaster venom, and ultimately would not even develop the typical serum sickness seen after receiving exorbitant amounts of antivenom. Symptoms of anaphylaxis and hypovolemic shock are very similar; yet swelling of the airways is not reported in hypovolemia. Moreover, there is no evidence that Miller was hypovolemic; loss of blood pressure has not been a serious problem. We are left with the question: are the activators of “*Lachesis* syndrome” essentially different from those that cause anaphylaxis? If they are, do these activators cause symptoms that mimic allergic reactions so closely that the difference is only in the pharmacology?

Once administered, the new *Lachesis*-specific antivenom from Toledo Zoo works magically; within hours the facial swelling is subsiding and by six hours it is not noticeable. Within 12 hours after the antivenom, his blood pressure, which never did fall extremely, appears nearly normal (120/70) and his heart rate only a little high (120). His neck is subtle with no lymphadenopathy, neck masses or tracheal deviation. His right arm has developed extreme swelling and blueness that extends to the level of 5 cm above the elbow—this is only to be expected—but his chest is clear to auscultation, his heart rhythm regular and there is no cyanosis. However, he remains a very sick man, for by now he has developed serious pulmonary complications after his many days on the respirator. The physician’s impressions are: (1) Acute renal insufficiency; nonoliguric at this time; (2) hyperkalemia (resolved after antivenom); (3) elevated CPK, likely secondary to rhabdomyolysis; (4) fibroginemia (improving after antivenom); and (5) respiratory failure. It is

not clear what this respiratory failure consists of, but the physician “rules out pneumonia” as the cause. The patient, who was just coming out of his induced coma after 5 days, described to me scenes of bloody fluid being pumped out of his airways. The blood cannot be positively confirmed as secondary to the envenomation, however; and could be blamed on the early and forced positioning of the intubation in the massively swollen trachea during what was evidently an emergency. Yet pulmonary congestion, quite another matter, did occur, and this would ultimately become the most serious secondary consequence of the bite or its treatment. Without full ventilatory support, fluids (e.g., normal saline 100 cc per hour), and loop diuretics (e.g., furosemide), Miller would have drowned in his own lungs. Pulmonary edema is a well known and often fatal complication in many crotalid snakebites. In more ordinary life, it may be caused by heart failure (as the heart fails, pressure in the veins going through the lungs starts to rise; as the pressure increases fluid is pushed into the airspaces); by damage directly to the lung (such as that caused by severe infection, smoke, poisonous gas); and by build up of body fluid as is seen in kidney failure. Since Miller was experiencing acute renal insufficiency (with hyperkalemia), pulmonary edema would be the likely result.

After 10 days and 50 vials of antivenom, Rodney Miller was guardedly released. A pale shadow of the healthy and muscular weight-lifter who had entered the hospital, he had lost 20 percent of his body weight (18 kg), most of it muscle mass. He required a walker to stand and existed in a greatly weakened state for months to come and could not go back to work. A rough and ragged cough—residue of his pulmonary issues—followed him for some 6 weeks, increasing his general haggardness. What happened? The whole envenoming is rather mystifying.

Yet it could have been much worse. He had been spared being murdered by a fasciotomy through presenting to the physicians an earlier edition of this book (my preaching against fasciotomy can be read in Chapter 23), and which his wise family members insisted was under no circumstances to be performed. Had surgery been performed he would undoubtedly have bled to death, or entered the irreversible hypovolemic shock-state seen in other cases. As it was, he developed no necrosis, nor any serious permanent deficit in the limb, and healed without scarring. The three outer fingers of his hand remained numb for 4 months, but full use of the hand returned after 6 months. He

developed no serum sickness, very unusual considering the enormous volume of antivenom he had received. Though an injection by one fang only, and this only shallowly embedded in the hard dorsal aspect of the finger (the 2.5 cm long fang would have encountered the bone), Miller's weirdly unusual snakebite would certainly have been fatal had early medical treatment, including quick intubation and life-support, not been available. And yet if he had died, Miller's autopsy might have concluded oddly that respiratory failure, not cardiovascular shock, had been what killed him.

I conclude from this case that: (1) Miller had not received enough venom to activate the lethal shock syndrome ("*Lachesis* syndrome") as it has been typically seen; and (2) that these activators (kininogenin protease and kallikrein proteinase) inspired another kind of autopharmacology ending in bradykinin build up (that mimicked but was not true anaphylaxis; i.e., swelling of the upper airways); this within itself could have been fatal; (3) that he was also perishing from the slower acting hemorrhagins and antifibrins which were notable in this case despite what was likely only a moderate envenomation (due to lack of the correct antivenom in the first two days post-bite); and that this led to (4) renal insufficiency, which inspired pulmonary edema and congestion resulting in pneumonia-like symptoms that were perhaps also complicated by the intubation.

Conclusions

The rapid systemic effects seen in these cases are so unusual in pitviper envenomings that one would be tempted to blame them on autopharmacological reactions rather than upon the direct consequences of what traditionally has been described as one of the slower acting ("hemotoxic") types of venom. Indeed, histamine shock shows some similarities: vomiting and diarrhea, increased salivation and difficulty swallowing (dry mouth), cyanotic skin on the feet and red spots on the neck, swelling of the airways, etc. All these effects can be seen in sensitivity to antivenom and serum sickness, and in rare cases, allergy to venom itself. Note, however that the violent abdominal convulsions (contractions of smooth muscles) are not typical of serum induced allergic shock. Indeed, venom-induced anaphylactic shock is itself very rare (Watt, 1989). Moreover, the first two envenomings did not provoke any systemic alterations whatever, nor have two subsequent envenomings by other pitvipers, *Bothrops asper* and *B. leucurus*, in the first

patient (Ripa). Russell (1983) reports that cyanosis, increased salivation (with alternately dry mouth), vomiting and diarrhea are not uncommon in normal crotalid envenomings (however usually much more delayed), where no allergy to venom exists. Benadryl in 2 cases (used in Bites 3 and 4) was of questionable worth, some 3-4 hours having elapsed before the patient was stabilized (in allergic reactions relief is usually prompt). The patients had no history of prior allergies, yet had nearly identical symptoms. There were no urticaria, angioneurotic edema (pharyngeal or laryngeal), or other disorders suggestive of vasoactive mediators in the first five cases, although there was severe swelling of the airways in the last, Bite 6. In this last case, however, it was not the impression of the physicians that they were witnessing a form of allergic shock per se.

Venom allergy is unnecessary to explain these symptoms. The syndrome of early nausea, vomiting, abdominal colic, diarrhea, sweating, hypotension, bradycardia and shock is becoming a familiar scene as more bushmaster envenomings are described; altogether forming a body of symptoms unique to these snakes (e.g., Jorge et al., 1997; Hardy and Silva, 1998). In a case reported in Torres et al. (1995), systemic effects occurred after only 45 minutes: intense sweating, vomiting, diarrhea, strabismus (eyes diverted to right and left), difficulty speaking and swallowing, slowing of the heart rate, and fall in systemic blood pressure with respiratory distress. A recent interactive envenoming in Costa Rica (recorded in Hardy and Silva, 1998) left the victim vomiting within minutes of the bite, with fainting and difficulties with speech occurring within 30 minutes of arrival at a medical facility. As noted by Hardy and Silva (1998), envenomings by Central American bushmasters are unique among pitvipers, showing "an assemblage of signs and symptoms that is not seen with other crotaline snakes." These six new cases, representing about one third of all known bushmaster envenomings of Central American origin, confirm this idea.

So what is happening in bushmaster bite and why do victims succumb so quickly? Rapid systemic alterations (as in Bites 3, 4 and 5) fit the profile of hypovolemic shock due to decreased circulating fluid volume, a condition which antivenom cannot restore. As Watt (1989) describes in bite cases of North American crotalids: "Clinical manifestations [of hypovolemia] include altered sensorium, hypotension, rapid heart rate and respiration (tachycardia and tachypnea, respectively), weak or absent pulses, pallor,

sweating, and cool skin.” He recommends oxygen and volume expansion with crystalloid (i.e., normal saline or Ringer’s lactate) provided there is no evidence of pulmonary congestion (these, among other treatments, proved effective in Bites 3 and 5). The rapid systemic developments in my two severe cases (and in Bites 5), even before swelling had become massive, suggests that a radically *decreased* circulating fluid volume was not the result of edema. Thus, while it is known that shock can occur due to massive swelling, where a third or more of the total blood volume may be lost into the envenomed extremity, the fluid volume loss must have been of other localized origin in these cases, where shock predated edema. As Russell (1983) notes: “Shock that follows within 30 minutes of envenomation may not be entirely due to the loss in fluid volume; it may be caused by a defect in blood distribution, presumably caused by intravascular pooling.” How quickly these agents make their way to the vital centers!

Dysphagia (difficulty in swallowing) is a seemingly neurologic effect, but it is more likely angioedema due to bradykinin formation from kininogenin protease and kallikrein proteinase, heavily present in bushmaster venom (and proportionately greater in the juvenile snake than in the adult; Chapter 26). The convulsive abdominal fasciculations, well appreciated by the envenomee, also resemble neurologic involvement. The pain is excruciating, and one of the most striking and memorable effects of the envenoming. This is quite distinct from the cramping of colic, but an intermittent spasm of the muscles producing a series of violent jolting or stabbing shocks recurring at intervals of 2 - 3 seconds and continuing relentlessly over several hours; the distress is such that the victim is soon overwhelmed. Disturbances of the autonomic nervous system, leading to vagal stimulation, form a clinical picture compatible with neurotoxic poisoning (Silva, 1980/1981; Fan and Cardoso, 1995). The vagus is the 10th cranial nerve, responsible for moving the muscles of speech and swallowing, and it transmits impulses to the heart and smooth muscles of the visceral organs, including the splanchnic nerves of the celiac (solar) plexus. Notably, envenoming by the common krait (*Bungarus caeruleus*), an elapine species with an extremely high mortality in the Indian subcontinent, results in paralysis of a number of cranial nerves; the 10th nerve among them (Theakston et al., 1988). Excessive salivation and fasciculating abdominal muscles are recorded symptoms of these bites. Is this or some similar involvement happening in bushmaster bite

as well; or is this course of the illness entirely distributive, from the standpoint of decreased tissue perfusion and the onset of shock? Again, these symptoms more parallel excessive bradykinin release from kininogenin protease and kallikrein proteinase (e.g., Silva 1981), than neurotoxicity. Symptoms of bradykinin formation include severe abdominal pain, accompanied by intense vomiting, weakness, watery diarrhea, and an unraised, non-itchy splotchy/swirly rash. All of these occurred in the most severe envenomings I have described; and a non-itchy, splotchy rash on my own skin was observed during episodes 3 and 4. Bradykinin has been described variously as producing contractions in the smooth muscles of test animals (e.g., Crouch et al., 1981; Azuma et al., 1983; Feres et al, 1994; Field et al, 1994; &c); and the jolting abdominal pain I have experienced in bushmaster envenoming fits more the description of sharp, unpleasant contractions than continuous pain.

Ditmars (1910) reports a case of death occurring within ten minutes from the bite of a bushmaster in the Panamá Canal Zone. So rapid a fatality Ditmars presumed due to the fangs puncturing an important blood vessel, but as these recent cases show, an intravenous injection of venom is not necessary to bring about the speedy incapacitation of the victim. Probably most rapid death sequences from bushmaster bite attributed to “the fangs striking a blood vessel” result from just such hypovolemic-shock episodes as are described in Bites 3, 4, and 5. They are simply intramuscular rather than intravenous injections, where the venom enjoys an almost equal toxic boost (Chapters 24 - 25). Rapid death from bushmaster bite appears to result from life-threatening hypotension occurring within an unusually short time frame; but intravenous inoculation would seem unnecessary, where an intramuscular injection would do much the same thing.

Hemolysis is mild and while some coagulopathy can be expected in severe envenomings, hemostatic disorders will rarely cause any significant coagulatory embarrassment comparable to what is seen in *Bothrops* and many other crotalids. Even local bleeding of the bite wounds is surprisingly mild after the initial bleeding of the fang punctures subsides. Hence addressing an apparent hypofibrinogenemia need not be a first order of treatment unless the patient is previously compromised. It seems evident that shock (hypotension) is the most immediately dangerous situation facing the patient, and the one needing first consideration by the attending physician. If the shock can be addressed promptly, the use of antivenom can be fore-

stalled if not available. It was not given in Bite 4, even though systemic effects were severe. When antivenom is given it should be given *in quantity*—not less than 10 ampoules [100 ml], and more than 20 ampoules in bites by adult snakes (see Chapters 23 - 26 for further treatment comments, and accounts of mortality due to insufficient antivenom). As not using antivenom exacerbates and prolongs local damage in all snakebites, its use should be considered even in potentially nonlethal envenomings.

Contradicting the hypothesis in Gutiérrez et al. (1990), the first and fourth envenomings clearly demonstrate substantial toxicity of the venom of neonates, at least to human beings. Supporting the Gutiérrez et al. (1990) hypothesis of low myotoxicity, there was no determinable myonecrosis in any case, even though in at least four of the six cases I have described, venom was injected directly into muscular tissue. Necrosis did not develop, and even the fang wounds did not abscess, something often observed of other species possessing less dangerous but ultimately more locally degrading venoms. Central American bushmaster bite is apparently atypical of most pitviper bites in that it produces rapid, grave circulatory alterations followed by unexpectedly low tissue destruction. There is, however, extreme edema and inflammation, and this may result in residual damage of the tissue, with accumulation of hemorrhagic debris in the muscle interstices (Chapters 23). The bites described in this chapter, all from the Central American group of bushmasters, cannot explain cases in South America where geographic variation in venom composition might exhibit a somewhat different symptomatology. It seems possible that greater hemorrhagic effects (and reduced shock effects) are seen in races of *L. muta* (but this is uncertain owing to confusion with *Bothrops* envenomings). At any rate, Bites 3, 4, 5 and 6 confirm reports of severe systemic alterations in bushmaster envenoming (Bolaños, 1982; Gutiérrez, 1995; Fan and Cardoso, 1995), but contradict reports of myotoxicity (Rosenfeld, 1971; Watt, 1989).

Contradicting Gutiérrez et al. (1990), edema and inflammation were noteworthy in neonate Bite 1 (antivenom might have prevented an even greater evolution), and massive in Bite 4, from a 2-month-old snake. Their hypothesis that “severe [envenoming] might not be the case in accidents caused by newborn *L. muta* [i.e., *L. stenophrys*]” leaves lingering questions, not the least of which in the definition of a “newborn.” At what age does the specimen cease being so? Gutiérrez et al. (ibid) propose that bushmaster venom does

not undergo ontogenetic change until after the first year of life; hence younger ones are not as venomous. This does not follow, since the bite of the merely 2-month-old bushmaster (in Bite 4), at only twice its hatch-size and small enough to coil up on the palm of your hand, produced severe symptoms. Though possessing twice as much venom as a 2-week-old specimen half its size, this is still a very small amount of venom (Chapter 21 and 25 suggests a probable amount). Surely this is toxicologically important. (Note that neonate bushmasters are extremely variable in size, ranging from 30 to 50 cm, and 30 to 80 g, at hatching; large newborns have larger fangs and substantially more venom than smaller ones). In support of Gutiérrez et al. (1990), I do not believe a newborn bushmaster 10 - 15 days old is capable of killing a healthy adult of my approximate body weight. A child or an elderly person would be more susceptible, however. Conversely, I do believe that, based on symptoms, an older neonate (such as the 2-month-old example described in Bite 4) would be well capable of killing an adult, especially someone of less robust constitution than myself. The proviso here would be that the route of inoculation is intramuscular or intravenous. Note that Bite 4 involved a very angry snake “hanging on” rather than releasing after the strike, and perhaps injecting a great portion of its venom supply. This was expressed directly into muscle, where it enjoyed a “toxic boost” not seen in subcutaneous delivery.

Without doubt, the bite of a 9-month-old bushmaster of 120 cm (Bite 3) could be rapidly fatal to an adult. Only through speedy supportive therapy and a large amount of antivenom was the victim saved. Though technically not a newborn, a 120 cm bushmaster is still less than 20 percent of its adult weight, and if female, two or three years away from being sexually mature. It is not an adult snake by any means. The prediction by Gutiérrez et al. (ibid) of “full toxicity of the venom achieved by year one of the bushmaster’s life” is difficult to accept, since Bite 4 involved a younger, and substantially smaller snake than Bite 3, and produced many of the same alterations, including the early systemic onslaught (but this will be resolved in Chapters 25 - 26). To make this prediction, however, we must redefine toxicity to include other qualities than those cytologically destructive ones described by Gutiérrez et al. (ibid). The neonate venom (as we shall see in Chapter 26) is quite distinctly toxic from the venom of adults. Nor could the smaller specimen be expected to deliver as much ven-

om nor to as great a depth intramuscularly, as the larger. Thus, without resorting to a theory of increased toxicity in the older snake, the greater severity of Bite 3 can be correlated with an increased ability to deliver venom, both in quantity and to intramuscular depth, where (if the LD₅₀ in mice has any bearing) the venom will enjoy a toxic increase over subcutaneous inoculation.

Confirming Gutiérrez et al. (1990), all five envenomings had negligible myotoxic and hemorrhagic effects, suggesting that local susceptibility to bushmaster venom is in some regards not dissimilar to the effects seen in mice. Only in Bite 6 was hemolysis considered a serious problem (but to what detriment is not known in this case involving a very large, 9-year-old snake). I believe that absence of hemorrhage and necrosis are two most important factors differentiating bushmaster bites from those of *Bothrops* and related genera in Central America. The full range of these effects can be compared all in one patient. The bite of a 3-month-old, 38 cm terciopelo (*Bothrops asper*) on my left index finger produced marked necrosis. The necrosis formed within two hemorrhagic bullae, each about 1.5 cm long, on the ball of the distal joint—one, where the fangs had penetrated, while the second, forming on the lateral aspect of the second joint, was a fully hemorrhagic eruption quite independent of the fang wounds (here the massive swelling had caused the finger to split open). Protecting the necrotic areas from disturbance and not debriding or draining them averted permanent damage. Systemic effects were inconspicuous and mild: an intense headache that lasted for several hours and an unpleasant metallic taste lingering in the mouth (in *Lachesis* bite, there is no metallic taste). Local pain was intense, like that of fire-burn. The pain in the bushmaster bite became more manageable ultimately, dulling to a numbing throb after a few days, whereas in the *Bothrops* bite, the pain continued with a deep fiery burn for some 6 weeks, radiating throughout the whole extremity and in sites remote from the inoculation site (elbow, forearm and back of the hand). Edema reached the shoulder and persisted for 21 days, afterwards receding to encompass only to the wrist and hand, which remained swollen until the 45th day. The finger remained tensely swollen and inflexible for 60 days, with continual burning pain. The necrotic tissue began sloughing off after this time. A lack of sensitivity has persisted in those areas until the present day and may be regarded as permanent. Hyperplasia of muscle and tendons was comparable to that

occurring in bushmaster Bite 4, requiring 6 months to regain full mobility of the envenomed finger. This little snake caused more skin damage than bites by bushmasters outweighing it by 30 times! Here the radically different effects of these two fundamentally different venoms can be seen in a single human “test dummy”—the *Bothrops* locally severe, the *Lachesis* systemically severe. The *Bothrops* bite left skin damage from necrosis, the bushmaster bites did not.

Bushmaster bite appears to be unusually dangerous for man, bringing grave symptoms within minutes—a speed exceeding even that of the technically more venomous elapids of Africa, Asia, and Australia. It is noteworthy that the bite of the taipan (*Oxyuranus scutellatus*), one of the world’s deadliest snakes (to mice!), usually does not usually produce severe systemic changes before 2 to 3 hours even when multiple envenomings occur (White, 1995). In bushmaster bite, there is no such delay, and dramatic systemic effects occur within minutes. The ability to inject a certain “critical minimum” of venom deep into muscle and/or intravenously activates uniquely hypotensive reactions with very little period of latency. Human beings (and probably all primates) appear to be unusually susceptible to bushmaster venom when this critical minimum is reached (Bites 3, 4 and 5); however, if the critical minimum is not reached (as in neonate Bite 1 and the nearly dry envenoming, Bite 2), the effects are much less deleterious. Ultimately, treatment may not even be necessary in these cases.

Bite 4 showed a case where only a small quantity of venom was injected by a small, 2-month-old snake (Chapter 21 reviews these yields). This amount, however, may have totalled more than half the contents of the snake’s glands due to the strike-hold nature of the bite (in normal strike-hold about 30 percent of available venom is injected; Chapter 21 and 25). Systemic alterations were rapid and severe, but once the dangerous early period (4 - 5 hours post bite) had passed, these subsided and did not return, even though local symptoms continued to evolve in severity over a period of weeks. These much more serious effects, both by small snakes, suggest that a certain activating volume of venom is necessary to advance the symptoms beyond the merely local to the systemic level. Perhaps the “newborn” (2-week-old) bushmaster, having less venom, is not able to supply this critical amount; or perhaps the limitations of subcutaneous envenoming (as was probable in Bite 1) did not magnify the activating effect. In other words, the intramuscular route achieved by the longer fanged 2-

month-old snake made an important difference. Moreover, the 2-month-old bushmaster in Bite 4, at twice the size of the 2-week-old bushmaster, would have roughly twice the venom at its disposal. Hence the lethality of bushmaster bite is a corollary of its size, reflecting both venom capacity and depth of inoculation (route). While the emphatically deadly serpens of clinical report have until now been of mature size, the critical minimum necessary to provoke the shock-death syndrome is therefore not restricted to adult specimens. Baby bushmasters, though rarely seen and rarely figuring in snakebite statistics, have the potential to produce grave effects as Bite 4 demonstrates; but freshly hatched specimens (1 to 14 days old) probably do not have enough venom to activate the fatal syndrome in a healthy adult (but more data is necessary). Bites 3, 5 and 6 describe what were inherently lethal envenomings from the standpoint of symptoms, and would likely have been so without quick treatment. Bite 6, involving a large adult specimen capable of delivering multiple lethal doses of venom, describes life-threatening swelling of the airways, coagulopathy and possible pulmonary bleeding, with what was probably only a small or at most moderate dose of venom only partially injected in a somewhat foiled strike delivery. Despite this, and massive amounts of antivenom, the patient's life was barely saved. Clearly individual susceptibility must vary enormously.*

In conclusion, bites by bushmasters of any size should be regarded as medical emergencies. Owing to the rapid "shock-like" syndrome that typifies these

bites, the victim is rendered almost immediately helpless and at the mercy of auxiliary care. If none exists—if the victim is alone and in a remote situation—he will probably be unable to mobilize himself sufficiently in order to reach help in time. Reviewing the literature of envenomation, one encounters again and again the stories of brave people bitten by deadly snakes, who have walked down out of the mountains to reach the medical attention that eventually saved them. This is probably not an option in bushmaster bite. One is able to hobble no more than a few dozen paces before being overtaken by a draining weakness, and collapsing, constrained to remain near where the attack has taken place. A saying attributed to South American Indians is not inappropriate: *If you are bitten by a makasneki (bushmaster), it is better to just lie down under a tree and rest for you will soon be dead.* Not a very restful furlough given the agonies described here! Chapter 25 elaborates on this "*Lachesis syndrome*," its meaning and effects, while Chapter 26 explores the pharmacology of the neonate venom, showing why drop for drop it is more dangerous to man than the venom of the adult snake.

**

* Two curious cases. "After a snakebite by the Costa Rican bushmaster (*L. stenophrys*), a 64-year-old patient developed cardiovascular shock and coagulopathy. After intensive care and antivenom treatment, he was discharged after 4 days but had to be hospitalized again 3 days later because of abdominal pain and bowel obstruction. An emergency laparotomy revealed a necrotic ileum and caecum, and an obstruction in the superior mesenteric artery. Until now, this type of intestinal ischemic complication after snakebite has not been reported in the literature."—Quoth Rosenthal et al., 2001. About seven weeks after the fourth of my bushmaster bites I was hospitalized for severe chest pains diagnosed tentatively as "pericarditis." Pain was severe and incapacitating, such that I had thought I was having a heart attack. Because no other cause could be established, and blood work could not determine a bacterial origin, the cause was deduced as "viral" by the examining physicians. At no point, however, was this conclusively determined and further monitoring over the next weeks did nothing toward confirming the idea. The pain was nearly unendurable; as though my heart were beating, as it were, on broken glass. I was able to sleep in a sitting up position only, the pain becoming overwhelming when I lay down. For over a month I consumed handfuls of indomethacin, a strong anti-inflammatory drug. Three months later the pain was still phantom. Pericarditis has a high correlation with iv drug use. I did not use iv drugs, but had most certainly been *injected*—by a hypodermic fang propelling a bizarre, possibly cardiotoxic venom containing possible Gram-positive and Gram-negative bacteria: *Escherichia*, *Aerobacter*, *Actinobacillus*, *Clostridium*, *Lactobacillus*, *Streptococcus* and *Staphylococcus*, etc., all variously harbored in the mouths of snakes. The physicians chose to manage my case with anti-inflammatory drugs only, and antibiotics were not given. While this helped control pain it did little toward speeding a resolution. The very long recovery period, three months in all, suggests this might not have been the right approach.

Literature Cited and Related Reading

- Beers, M. H., and R. Berkow. 1999. The Merck manual of diagnosis and therapy. Merck Research Laboratories. Whitehouse Station, N.J.
- Bjarnason, J. B., and J. W. Fox. 1994. Hemorrhagic metalloproteinases from snake venoms. *Pharmacol Ther* 62, 325-372.
- Blaylock, R.S. 2000. Antibacterial properties of KwaZulu Natal snake venom. *Toxicon*. 38:1529-34.
- Bogert, C. M. 1943. Dentitional phenomena in cobras and other elapids, with notes on adaptive modifications. *Bull. Am. Mus. Nat. Hist.* 81: 285-360.
- Bolaños, R. 1972. Toxicity of Costa Rican snake venoms for the white mouse. *Amer. Jour. Trop. Med. Hyg.* 21:360-363.
- Bolaños, R. 1982. Las serpientes venenosas de Centroamérica y el problema del ofidismo. Primera parte. Aspectos zoológicos, epidemiológicos y biomédicos. *Rev. Costarr. Cienc. Méd.* 3:165-184.
- Bolaños, R., G. Muñoz and L. Cerdas. 1978. Toxicidad, neutralización e inmunoelectroforesis de los venenos de *Lachesis muta* de Costa Rica y Colombia. *Toxicon* 16:295-300.
- Bolaños, R., O. Rojas and C. E. Ulloa Flores. 1982. Aspectos biomédicos de cuatro casos de mordedura de serpiente por *Lachesis muta* (Ophidia: Viperidae) en Costa Rica. *Rev. Biol. Trop.* 30:53-58.
- Campbell, J. A. and E. D. Brodie, Jr. (eds.) 1992. *Biology of the pitvipers*. Tyler, Tex.: Selva.
- Campbell, J. A. and W. W. Lamar. 1989. *The venomous reptiles of Latin America*. Ithaca, NY: Cornell University Press.
- Cedergren, E, Johansson, B., Heilbronn, E., and Widlund, L. 1973. Ultrastructural analysis of phospholipase A induced changes in membranes of synaptic regions in rat motor cortex. *Ex. Brain Res.*, 16:400.
- Crouch, M.F., M. L. Roberts and K. A. Tennes (1981). Mepacrine inhibition of bradykinin-induced contractions of the rabbit ear vein. *Agents and Actions*. Vol. 11; 4.
- Dart, R. C., J. T. McNally, D. W. Spaite and R. Gustafson. 1992. The sequelae of pitviper poisoning in the United States. In: *Biology of the Pitvipers*, (eds.) J. A. Campbell and E.D. Brodie Jr. Tyler, Tex.: Selva.
- Dart, R. 1999. *Int J Med Toxicol* 1999; 2(1):1, Hall EL. *Ann Emerg Med* 2001;37:175-80).
- DaSilva, N. J., S. D. Aird, C. Seebart and I. I. Kaiser. 1989. A gyroxin analog from the venom of the bushmaster (*Lachesis muta muta*). *Toxicon* 27:763-771.
- Diniz, M. R., and E. B. Oliveira. (1992). Purification and properties of a kininogenin from the venom of *Lachesis muta* (bushmaster). *Toxicon* 30, 247-258.
- Ditmars, R. L. 1910. *Reptiles of the world: Tortoises and turtles, crocodylians, lizards and snakes of the eastern and western hemispheres*. NY: Sturgis and Walton Co.
- Esquerre, C. 1976. The minimum lethal dose (MLD) of venoms from Peruvian Crotalidae Snakes. San José, Costa Rica: Fifth international symposium on animal, plant, and microbial toxins abstracts.
- Estep, K., T. Poole, C. W. Radcliffe, B. O'Connell and D. Chiszar. 1981. Distance traveled by mice (*Mus musculus*) after envenomation by prairie rattlesnakes (*Crotalus viridis*). *Bull. Psychon. Soc.* 18:108-110.
- Estevao-Costa, M. I., Diniz, C. R., Magalhaes, A., Markland, F. S., and Sanchez, E. F. 2000. Action of metalloproteinases mutalysin I and II on several components of the hemostatic and fibrinolytic systems. *Thromb Res* 99, 363-376.
- Fan, H. W., and J. L. Cardoso. 1995. Clinical toxicology of snake bites in South America. In: J. Meier and J. White, (eds.) *Handbook of clinical toxicology and animal venoms and poisons*. New York: CRC press.
- Faraci, F. M., M. A. Klotz, H. W. Shirer, A. Orr and J. W. Trank. 1980. Characteristics of bulbus cordis mechanoreceptors in the pond turtle *Pseudemys scripta elegans*. *Trans. Kansas Academy of Sciences* 83(1):132.
- Farmer, S.G., R.M. Burch, C.J. Dehaas, J. Togo and L.R. Steranka. (1989) [Arg1-Phe7]-substituted bradykinin analogs inhibit bradykinin- and vasopressin-induced contractions of the uterine smooth muscle. *JPET* Vol. 248. No. 2. 677-681.
- Felicori, L. F., C. T. Souza, D. T. Velarde, A. Magalhaes, A. P. Almeida, S. Figueiredo, M. Richardson, C. R. Diniz, and E. F. Sanchez. 2003. Kallikrein-like proteinase from bushmaster snake venom. *Protein Expr Purif* 30; 32-42.

- Feres, T., E. Frediani-Neto, TB Paiva. 1994. Mechanism of smooth muscle contraction and relaxation mediated by kinin receptor. *Braz J Med Biol Res* 27:1911-6.
- Fitch, H. S. 1981. Sexual size differences in reptiles. *Miscellaneous Publications of the Museum of Natural History, University of Kansas* 70:1-72.
- Field, J.L., S.K. Butt, I.K. Morton, and J.M. Hall. (1994). Bradykinin B2 receptors and coupling mechanisms in the smooth muscle of the guinea-pig taenia caeci. *Br. J. Pharmacol.* 113(2): 607-13.
- Fuly A.L., S. C. Elias, R.B. Zingali, J. A. Guimarães, and P.A. Melo. Myotoxic activity of an acid phospholipase A2 isolated from *Lachesis muta* (Bushmaster) snake venom *Toxicon* 2000; 38: 961–72
- Gutiérrez, J. M. 1995. Clinical toxicology of snakebite in Central America. In: J. Meier and J. White, (eds.), *Handbook of clinical toxicology of animal venoms and poisons*. New York: CRC Press.
- Gutiérrez, J. M. and F. Chaves. 1980. Efectos proteolítico, hemorrágico, y mionecrótico de los venenos de serpientes costarricenses de los géneros *Bothrops*, *Crotalus* y *Lachesis*. *Toxicon* 18:315-321.
- Gutiérrez, J. M., F. Chaves and R. Bolaños. 1980. Estudio comparativo de venenos de ejemplares recién nacidos y adultos de *Bothrops asper*. *Rev. Biol. Trop.* 28:341-351.
- Gutiérrez, J. M., F. Chaves and R. Bolaños. 1990. Ontogenetic changes in the venom of the snake *Lachesis muta stenophrys* (bushmaster) from Costa Rica. *Toxicon* 28:419-426.
- Gutiérrez, J. M., G. Rojas and L. Cerdas. 1987. Ability of a polyvalent antivenom to neutralize the venom of *Lachesis muta melanocephala*, a new Costa Rican subspecies of the bushmaster. *Toxicon* 25:713-720.
- Giovanni-De-Simone, S., A. S. Aguiar, A. R. Gimenez, K. Novellino and R. S. de Moura. 1997. Purification, properties and N-terminal amino acid sequence of kallikrein-like enzymes from the venom of *Lachesis muta rhombeata*. *J. Protein Chem.* 16(8):809-818.
- Hardy, D. L., Sr. 1992. A review of first aid measures for pitviper bite in North America, with an appraisal of the Extractor (TM) and stun gun electroshock. In: J. A. Campbell and E. D. Brodie Jr. (eds.), *Biology of the pitvipers*. 405 - 14 Tyler. Tex.: Selva.
- Hardy, D. L., Sr. and J. Silva Haad. 1998. A review of venom toxinology and epidemiology of envenoming of the bushmaster (*Lachesis*) with report of a fatal bite. *Bull. Chicago Herp. Soc.* 33(6):113-123.
- Hayes, W. K. and J. G. Galusha. 1984. Effects of rattlesnake envenomation upon mobility of male wild and laboratory mice. *Bull. Maryland Herp. Soc.* 20:135-144.
- Huang, M. Z., P. Gopalakrishnakone, M. C. Chung, and R. M. Kini. 1997. Complete amino acid sequence of an acidic, cardiotoxic phospholipase A2 from the venom of *Ophiophagus hannah* (King Cobra): a novel cobra venom enzyme with “pancreatic loop”. *Arch Biochem Biophys* 338, 150-156.
- Hulin., A., Ochoa and J. M. Desbordes. 1982. Envenimations par des crotalides en Guyane Francaise. *Med. D’Afrique Noire* 29:249- 225.
- Kini, R. M., and Evans, H. J., 1992. Structural domains in venom proteins: evidence that metalloproteinases and nonenzymatic platelet aggregation inhibitors (disintegrins) from snake venoms are derived by proteolysis from a common precursor. *Toxicon* 30, 265-293.
- Kondo, H., S. Kondo, S. Sadahiro, K. Yamauchi, A. Ohsaka, R. Murata. 1972. Estimation by a new method of the amount of venom ejected by a single bite of *Trimeresurus* species. *Japan. J. Med. Sci. Biol.* 25:123-131.
- Lucas, S. M., and Jurg Meier. 1995. The biology and distribution of spiders of medical importance. In: J. Meier and J. White, (eds.), *Handbook of clinical toxicology of animal venoms and poisons*. New York: CRC Press.
- Madsen, T. and R. Shine. 1992. A rapid, sexually-selected shift in mean body size in a population of snakes. *Evolution.* 46:1220-1224.
- Magalhaes, A. and C.R. Diniz. 1979. Purification and partial characterization of the thrombin-like enzyme from the venom of *Lachesis muta noctivaga*. *Toxicon* 17, Suppl. No. 1:112.
- Magalhaes, A., R. N. Ferreira, M. Richardson, S. Gontijo, A. Yarleque, H. P. B. Magalhaes, C. Bloch, E. F. Sanchez. 2003. Coagulant thrombin-like enzymes from the venoms of Brazilian and Peruvian bushmaster (*Lachesis muta muta*) snakes. *Comparative Biochemistry and Physiology Part B* 136:255-266.

- Marsh, N.E., B. C. Whaler. 1984. The Gaboon viper (*Bitis gabonica*); its biology, venom components and toxinology. *Toxicon* 22 (5):669-94
- Mellor, N. H. and J. C. Arvin. 1996. Case report. A bushmaster bite during a birding expedition in lowland southeastern Peru. *Wildn. Environmental. Med.* 3:236-240.
- Milani Junior R, MT Jorge, FP de Campos, FP Martins, A Bousso, JL Cardoso, LA Ribeiro, HW Fan, FO Franca, IS Sano-Martins, D Cardoso, C Ide Fernandez, JC Fernandes, VL Aldred, MP Sandoval, G Puerto, RD Theakston and DA Warrell. 1997. Snake bites by the jararacucu (*Bothrops jararacussu*): clinicopathological studies of 29 proven cases in Sao Paulo State, Brazil. *QJM*, Vol 90, Issue 5 323-334, Oxford University Press.
- Minton, S. A. Jr. and M. R. Minton. 1969. Venomous reptiles. New York: Scribner.
- Mitchell, S. W. 1860. Researches upon the venom of the rattlesnake. *Smithson. Contrib. Knowledge* 1860:1-139.
- Pough, F. H. and J. D. Groves. 1983. Specialization of the body form and food habits of snakes. *Am. Zool.* 23:443-454.
- Reid, H. A. 1976. Venoms and Antivenoms. (Review on Glass, T. G. Jr. Early debridement in pitviper bites. *J.A.M.A.*, 235:2513, 1976). *Abstracts on Hygiene* 51:1139.
- Ripa, D. 1994. Reproduction of the Central American bushmaster (*Lachesis muta stenophrys*) and the black-headed bushmaster (*Lachesis muta melanocephala*) for the first time in captivity. *Bull. Chicago Herp. Soc.* 29(8):165-183.
- Ripa, D. 1997. Range extension for *Bothrops leucurus*. *Bull. Chicago Herp. Soc.* 32(2):25-26.
- Ripa, D. 1999. Keys to understanding the bushmasters (Genus *Lachesis* Daudin, 1803). *Bull. Chicago Herp. Soc.* 34(3):45-92.
- Rosenfeld, G. 1971. Symptomatology, pathology, and treatment of snake bite in South America. Pp. 345-383. In: W. Bucherl and E. E. Buckley, (eds.), *Venomous animals and their venoms*. Vol. 2. New York: Academic Press.
- Rucavado, A., E. Flores Sanchez, A. Franceschi, A. Magalhaes, J. M. Gutierrez. 1999. Characterization of the local tissue damage induced by LHF-II, a metalloproteinase with weak hemorrhagic activity isolated from *Lachesis muta muta* snake venom. *Toxicon* 37:1297-1312.
- Russell, F. E. 1983. Snake venom poisoning. Greatneck, NY: Scholium International.
- Sanchez, E. F., T. V. Freitas, D. L. Ferreira-Alve, D. T. Valverde, M. R. Diniz, M. N. Cordeiro, G. Agostini-Cotta, C. R. Diniz. 1992. Biological activities of venoms from South American snakes. *Toxicon* 30:95-103.
- Sanchez, E. F., C. I. Santos, A. Magalhaes, C. R. Diniz, S. Figueiredo, J. Gilroy, M. Richardson. 2000. Isolation of Proteinase with Plasminogen-Activating Activity from *Lachesis muta muta* (Bushmaster) Snake Venom. *Archives of Biochemistry and Biophysics*. Vol. 378, No. 1: 131-141
- Silva Haad, J. L. 1980/1981. Accidentes humanos por las serpientes de los generos *Bothrops* y *Lachesis*. *Mem. Inst. Butantan* 44/45:403-423.
- Silva, L. M., C. R. Diniz and A. Magalhaes. 1985. Purification and partial characterization of an arginine ester hydrolase from the venom of the bushmaster snake, *Lachesis muta noctivaga*. *Toxicon* 23(4): 707 - 718.
- Solórzano, A. and L. Cerdas. 1986. A new subspecies of the bushmaster, *Lachesis muta*, from southeastern Costa Rica. *J. Herpetology* 20(3):463-466.
- Solórzano, A. and L. Cerdas. 1989. Reproductive biology and distribution of the terciopelo, *Bothrops asper* Garman (Serpentes: Viperidae) in Costa Rica. *Herpetologica*. 45(4):444-450.
- Solórzano-López, A., M. Santana and H. W. Greene. 1987. Reproductive biology of *Lachesis muta stenophrys* (Serpentes: Viperidae) in Costa Rica. *Abst. Jt. Ann. Mtg. SSAR Herpet. League* :146.
- Taylor, E. H. 1951. A brief review of the snakes of Costa Rica. *Univ. Kansas Sci. Bull.* 34:1-188.
- Thomas, R. G. and F. H. Pough. 1979. The effect of rattlesnake venom on digestion of prey. *Toxicon* 17:221-228.
- Torres, J. R., M. A. Torres and M. A. Arroyo-Parejo. 1995. Coagulation disorders in bushmaster envenomation. [Letter] *Lancet* 346:449-450.
- Vial, J. L. and J. M. Jiménez-Porrás. 1967. The ecogeography of the bushmaster, *Lachesis muta*, in Central America. *American Midland Naturalist*. 78:182-187.

Watt, G. 1989. Snakebite treatment and first aid. In: J. Campbell and W. W. Lamar (eds.), The venomous reptiles of Latin America. Ithaca NY: Cornell University Press.

White, J. 1995. Clinical toxicology of snake bite in Australia and New Guinea. In: J. Meier and J. White, (eds.) Handbook of clinical toxicology and animal venoms and poisons. New York: CRC press.

Yarleque, A. S. Campos, E. Escobar, F. Lazo, N. Sanchez, S. Hyslop, N. A. Marsh, P. J. Butterworth and R. G. Price. 1989. Isolation and characterization of a fibrinogen-clotting enzyme from venom of the snake *Lachesis muta muta* (Peruvian bushmaster). *Toxicon* 27(11):1189-1197.

